

**SURGICAL AFFECTION OF THE HOOF IN HORSES WITH
SPECIAL REFERENCES TO THEIR TREATMENT**

A Thesis

**Presented to the Graduate School
Faculty of Veterinary Medicine, Alexandria University
In Partial fulfillment of the
Requirements for the Degree**

Of


Master of Veterinary Science

In

(Surgery)

By

Haitham Ibrahim Ali Shower



2006

**" Surgical affections of the hoof in Horses with
special References to their Treatment "**

**Presented by
Haitham Ibrahim Ali Shawer**

**For the Degree
Master of Veterinary Science**

**In
(Surgery)**

By

Examiners Committee:

Prof. Dr. Kamal El-Din A. Fouad
Professor of Surgery
Faculty of Veterinary Medicine –Cairo University

Prof. Dr. Moustafa M. Kassem
Professor of Surgery
Faculty of Veterinary Medicine –Alexandria University

Prof. Dr. Samir R. Noh
Professor and the Head of Surgery Department
Faculty of Veterinary Medicine –Alexandria University

Dr. Ramadan E. Abdel-Wahed
Assistant Professor of Surgery
Faculty of Veterinary Medicine –Alexandria University

Approved

K. Fouad

Kassem

S. R. Noh

Abdel-Wahed

UNDER SUPERVISION OF

PROF. DR. SAMIR R. NOUH
PROFESSOR AND THE HEAD OF SURGERY DEPARTMENT.
FACULTY OF VETERINARY MEDICINE
ALEXANDRIA UNIVERSITY

S. R. Noh

AND

DR. RAMADAN E. ABD EL-WAHED
ASSISTANT PROFESSOR OF SURGERY
FACULTY OF VETERINARY MEDICINE
ALEXANDRIA UNIVERSITY

Abdelwahed

بِسْمِ اللَّهِ الرَّحْمَنِ الرَّحِيمِ

بِسْمِ اللَّهِ الرَّحْمَنِ الرَّحِيمِ

"وأعدوا لهم ما استطعتم من قوة ومن رباط الخيل

ترهبون به عدو الله وعدوكم ."

(صدق الله العظيم)

سورة الأنفال . الآية 60

عن قتيبة عن عبد العزيز بن محمد عن سميل

بن أبي صالح عن أبيه عن أبي هريرة قال: قال:

رسول الله صلى الله عليه وسلم :

"الخيال معقود في نواصيها الخير إلى يوم القيامة .

وأهلها معانون عليهما . والمنفق عليهما كالباسط يده

بالصدقة."

(حديث شريف)

Acknowledgment

First of all prayful to our merciful **GOD** who gives me every thing I have.

I would like to express my deepest gratitude and appreciation for the great kindness, continuous encouragement and super vision of **Prof. Dr. Samir R. Nouh**, professor and the head of surgery department , faculty of veterinary medicine ,Alexandria University, for his generous supervision, valuable advices, guidance continuous assistance, continous encourageand continous great efforts, realy father advise through out this work.

It is of great pleasure for me to express my thank and indebtedness to Ass. professor **Dr. Ramadan E. Abd-Elwahed** Ass. Professor of surgery, faculty of veterinary medicine ,Alexandria University, for his great efforts, careful guidance and cautious aid during the conduction of this thesis.

Grateful thanks are due to the staff members of the surgery department faculty of veterinary medicine, Alexandria University.

I wish to thank the valuable help of the team work in Brook hospital for animal care (Alexandria clinic).

finally thanks are due to the valuable help of team work principle veterinary hospital of the army veterinary services.

CONTENT

	<u>page</u>
Introduction	1
Review of Literature	
Hoof anatomy.....	2
Hoof Histology.....	5
Most Common disorders in equine hoof.....	7
Materials and Methods	34
Results	41
Discussion	60
Summary	68
References	71
Arabic Summary	

Introduction

In Egypt, horses still represent a group of farm animals. They play an important role in the economy of our people. According to the latest statistical data , the number of this species exceeds million heads including donkeys and mules of which about 90% constitutes draught animals used mainly for local transportation. The other 10% comprises racers, riding, jumper and sport horses.

Chronic affections are much more abundant among these species, simply because of the mal-manipulation of the cases by the owners, from one hand, and the lack of restricted laws against cruelty of animals from the other hand, and also more serious because of the permanent claudication the ensued.

Unfortunately, limb affections causing lameness among these animals are up till now not well assessed or even detected and classified. The symptoms and diagnosis are still in need of detailed description and further full information especially under our own environmental conditions.

If the animal is not absolutely locomotor efficient, it is unable to work and unless it is quickly restored to health it soon becomes uneconomic. Heavy animals, rough concrete roads, diet excessively high in energy and low fiber and hereditary factors; all play roles in the development of affections causing lameness.

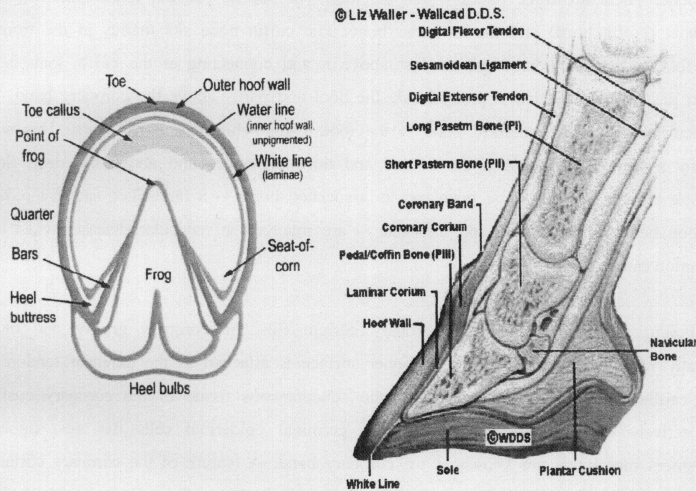
According to our clinical observation most of the lame conditions are due to hoof injuries of which laminitis , podotrochlites, picked up nail, thrush, quitter, coronitis are the most available.

Aim of the work:

For the previous reasons this study has been planned to throw a light on the incidence, symptoms, diagnosis and treatment of hoof affections among these animals.

Review of Literature

1- Hoof anatomy



McClure (1993) and Miller(1999), reported that wall of the hoof is composed of a horny material that is produced continuously and must be worn off or trimmed off. The hoof wall does not contain blood vessels or nerves. In the front feet, the wall is thickest at the toe; in the hind feet the hoof wall is of a more uniform thickness. The wall, bars and frog are the weight-bearing structures of the foot. The sole covers the bottom surface of the hoof and is about one-third. It is similar to the wall, made up of tubules. The tubules curl near the ground surface, which explains its self-limiting growth and causes shedding. On a healthy foot, the sole will be slightly concave, elevated off the ground. Normally the sole does not contact the ground. The frog is the triangular mass that lies between the bars of

the foot at the heels. It is almost 50% water, and therefore is quite soft and pliable. The point of the frog is called the apex, the grooves along the 4 sides are the sulci and the depression along the bottom surface called the central sulcus or cleft. Inside the hoof, lateral cartilages extend back and up from the inner and outer sides of the third phalanx. These cartilages are flexible, but as the horse ages, they are usually ossified and replaced by bone. There are three bones within the foot. The second phalanx (short pastern), third phalanx (coffin bone) and the navicular bone. The coffin bone sits mainly at the front of the foot and appears hoof-shaped. Just above it and connecting at the coffin joint is the short pastern, a bone that is partly inside the hoof and partly above the coronary band. The navicular bone is the smallest bone in the foot, lying behind the coffin joint. This small bonny structure lies between the second and third phalanges and above the deep flexor muscle tendon. The navicular bone and its associated bursa -- a fluid-filled sac that reduces friction between the tendon and the bone -- are involved in navicular disease, which is a common cause of lameness.

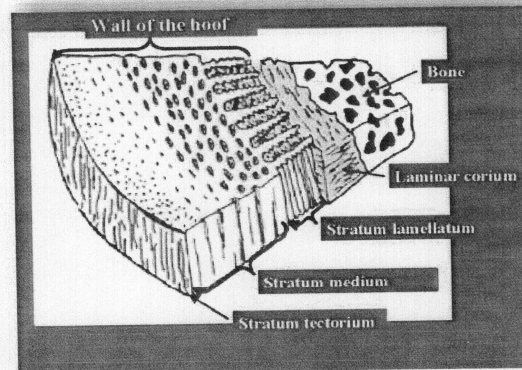
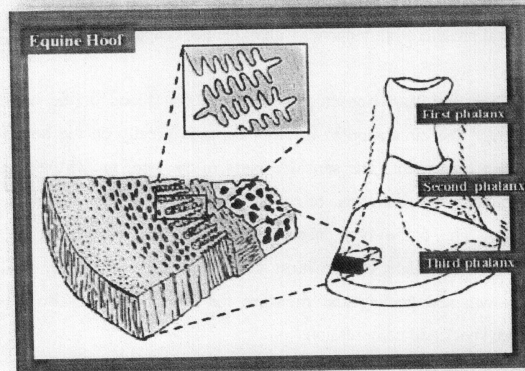
Pollitt, (1995) said that the coronary corium fills the coronary groove and blends distally with the lamellar corium. Its inner surface is attached to the extensor tendon and the cartilages of the distal phalanx by the subcutaneous tissue of the coronary cushion. Collectively the coronary corium and the germinal epidermal cells that rest upon its basement membrane are known as the coronary band. A feature of the coronary corium is the large numbers of hair-like papillae projecting from its surface. Each tapering papilla fits into one of the holes on the surface of the epidermal coronary groove and in life, is responsible for nut rating an individual hoof wall tubule.

Pollitt, (1998) reported that The highly vascular corium or dermis (popularly the "quick") underlies the hoof wall and consists of dense matrix of tough connective tissue containing a network of arteries, veins and capillaries, and sensory and vasomotor nerves. All parts of the corium, except for the lamellar corium, have papillae that fit tightly into the holes in the adjacent hoof. The lamellar corium has dermal lamellae that interlock with the epidermal lamellae of the inner hoof wall and bars. The corium provides the hoof with

nourishment and its dense matrix of connective tissue connects the basement membrane of the dermal-epidermal junction to the periosteal surface of the distal phalanx and thus suspends the distal phalanx from the inner wall of the hoof capsule.

Emery, Miller, and Van Hoosen (1977) stated that blood of the hoof is supplied by the digital arteries. The circulation in the foot depends greatly on the hoof's expansion and contraction during movement. The sensitive parts of the hoof are virtually a mass of blood vessels. The highest concentration of blood vessels is in the coronary band and the sensitive laminae. The coffin bone itself is highly porous, containing many arteries and veins. The coffin bone might be the most vascular one in the horse. The blood supplies nutrition for growth and healing and moisture for horn health. It also acts as a hydrolic cushion to absorb shock and compression.

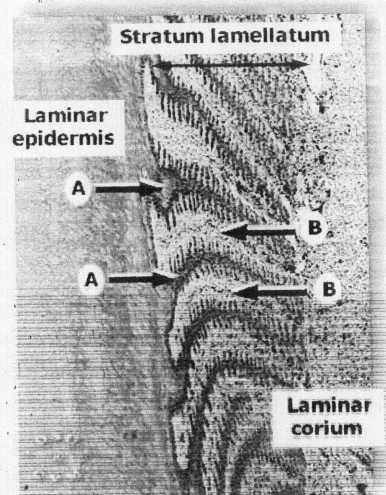
2- Hoof Histology:



According to Stump (1967) and Dellman (1981), the hoof is characterized by a thin inner layer of stratum germinativum next to the corium and a heavy outer layer of stratum corneum. Histologically the hoof wall is composed of three layers, stratum tectorium or periopic epidermis (stratum externum), stratum medium and stratum lamellatum (Stratum

internum). The stratum externum, is a thin layer of soft flaky tubular horn originates from the germinal layers of the epidermis of the periople. The periople is a ring of soft non pigmented tubular horn that forms at the junction of the skin and hoof wall. This protective layer, the stratum tectorium reduces moisture loss from the wall. The middle layer (the stratum medium), forming the bulk of the wall, consists of tubular and intertubular hard horn. It is produced by the stratum germinativum which lies in the coronary groove adjacent to the coronary corium by which it is nourished. The stratum germinativum covering the vertically directed papillae of the coronary corium proliferates cells off the sides of the papillae which cornify and form the tubular horn. Cross section profiles of the tubules may be circular, oval or wedge shaped and have a central region of loose elements. The keratinized cells oriented around the medulla in fairly tight coils. The middle zone form loose spirals, and outer zone is another layer of tight coils. This coiled, spring-like arrangement of the cells of tubular horn helps to dampen the compression of the hoof when it strikes a hard surface. The cells of the germinal layer located between the papillae are oriented parallel to the coronary border. These intercapillary proliferate, cornify and form the intertubular horn which fills the area around the tubules. The stratum medium may be pigmented except for its deepest portion which is always non pigmented.

Pollitt, (1998) said that the innermost layer of the hoof wall and bars of horses and ponies is named the *stratum lamellatum* (layer of leaves) after the 550-600 epidermal lamellae (primary epidermal lamellae) which project from its surface in parallel rows. Examination of the hoof capsule, with its contents removed, shows that the lamellae of the dorsal hoof wall are shaped like long thin rectangles approximately 7mm wide and 50mm long. One long edge of the rectangle is incorporated into the tough, heavily keratinised hoof wall proper (*stratum medium*) and the other long edge is free, facing the outer surface of the distal phalanx. The proximal short edge is curved and forms the curved shoulder of the coronary groove. The distal short edge merges with the sole and becomes part of the white zone visible at the ground surface of the hoof.



Charlotte. (2002) described that the Wall of the Hoof consist of, *stratum externum or tectorium* is an extension of the perioplic epidermis and is composed of cornified epithelial cells which appear as a soft, white, shiny material. This tissue attaches the hoof to the epidermis of the skin of the foot, *stratum medium* or coronary epidermis is composed of prominent tubular and intertubular horn, and this layer comprises the bulk of the wall of the hoof, *stratum internum* or *stratum lamellatum* is the epidermis in the laminar region.

3- Most common affection in equine hoof :

Laminitis:

Laminitis, founder or foot fever was defined by frank (1964), Adams (1974) Jacobson and Hayes (1978) and Johnson (1972) as an inflammation of the sensitive laminae of the foot, frequently affecting the front feet and sometimes all four feet were affected while less frequently one foot and rarely the hind feet alone.

Johnson (1982) described laminitis as an inflammation of the pedal laminae. All four feet could be affected but the front one are more commonly involved.

Annon (1966) defined founder as primarily non infectious inflammation of sensitive laminae, affecting the fore feet, in some time all four feet, or one foot affected. Laminitis often occurs in the presence of digestive disturbance with impaction of caecum.

Charlotte. (2002) stated that laminitis (acute laminar degeneration) is an inflammation of the laminae within the hoof. Many pathophysiologic mechanisms are thought to cause laminitis, among them vasoconstriction within the digit, perivascular edema, arteriovenous shunting of blood at the level of the coronary band, venoconstriction and microthrombosis. These lead to less than normal perfusion of blood to the digit resulting in ischemia, edema and eventually necrosis of the laminae.

Barakat (2000) reported that Blood pressure and pulse are important early indicators of the horse hoof disease laminitis. Learning to take and interpret them when your horse is healthy can save precious time in an emergency. The blood-pressure cuff is an accurate, but underutilized tool in detecting laminitis. The average horse's systolic reading, which indicates the force of blood pumped from the heart, will remain between 110 and 120. (Diastolic pressure is rarely an indicator of disease in horses.) Early in an episode of laminitis, a horse's blood pressure shoots up by 20 to 30 points or more as blood is forced through the constricted vessels within the hooves. This increase occurs as much as 12 hours before the obvious physical signs of laminitis appear, a small window of time to begin aggressive treatment that may prevent the worst damage. A strong pulse can mean a few different things. If the pulse is stronger only in one leg, for example, chances are an infection--from a wound or abscess, for instance--is present. A bounding pulse in both front legs, however, is an early sign of laminitis, especially when the blood pressure is also elevated. Taking a horse's pulse isn't simply a matter of putting a finger to an artery, however. Equine blood vessels can be difficult to locate; you'll need to master a three-fingered technique to glean the most useful information. Be prepared: Taking an accurate reading of a horse's pulse requires lots of practice.

Coffman and Garner (1972) and Baird (1933) mentioned that the commonly recognized causes include dietetic errors or alimentary induced laminitis due to over feeding on too stimulating or irritating diet as wheat, corn, barley (grain founder), ingestion of lush grass pasture containing clover and alfa-alfa (grass founders) or drinking large amount of cold water especially over heated horses (water founder).

Moore (1979) stated that the mechanism of induction of laminitis is not clear and appears multifactorial, but endotoxine has been implicated with the disease. While, Ekfalck, Rodriguez and Obel (1992) mentioned that through whatever mechanism, a reduction of blood flow to the laminae occurs, resulting in ischemic necrosis and subsequent physical breakdown of these tissues.

Annon (1966), Colles and Jeffcott (1977), El-Guindy (1981) observed that in chronic form of laminitis the animal during movement extends the affected limbs forward and bears most of weight on heel. The affected hoof was elongated and showed a central depression of the wall were seen close at the toe and widely separated at the quarter and heel.

Diverst (2003) found that organ thrombosis and laminitis are life-threatening complications in horses with acute gastrointestinal disease, especially diseases that cause disruption of the protective mucosal barrier. Prevention of these complications should be a high priority when treating horses with gastrointestinal diseases because even with proper and intensive treatments, laminitis or organ thrombosis may not be curative.

Ackerman, Garner, Coffman, Hahn, and Johnson (1975) said that there are definite age, sex, season, and breed risk factors associated with equine laminitis. It was found that, male and female similar risks, however, castration of male reduced the risk by nearly half. The preponderant age ranges for mare was 4-7 years, whereas for male it was 7-10 years; this finding suggested predisposing factor associated with maturity

Hallet (1936), O'Connor (1958), Adams (1974), and Jeffcott (1977) mentioned that laminitis often lead to changes in the hoof wall (founder) caused by inflammation in the coronary band. Changes in the third phalanx such as rotation and osteitis are common sequallae.

Hood, and stephans, (1981) found that horse shoeing have a higher risk of laminitis in the late summer and early fall, which is the peak of shoeing season. During this time, horses are often under a lot of stress and are usually being fed high carbohydrate (grain) diet.

Dom (1975) recommended that male and female horses had similar risks of laminitis; however, they found that castration reduced such risk by nearly the half. The age in which laminitis was found to be frequent in mares was about four to seven years while in males from seven to ten years.

Adams (1974) and Ackerman ,Garner Coffman, and Clement (1975) mentioned that separation of the sensitive and insensitive laminae (seedy toe) usually accompanied cases of chronic laminitis. In many instances, infection might penetrate the sensitive laminae via the separation at the white line giving rise to septic laminitis.

Adams (1974) and Emery, Miller, and Hossen (1977) attributed some cases of laminitis to hormonal factors or the use of potent fertilizers on pastures and hay crops.

Obel (1948) induced experimental laminitis in the horses and classified the symptoms into four different degrees.

Adams (1974), Colles and Jeffcott (1977) and Johnson (1982) found that the symptoms of laminitis were developed rapidly and started with depression anorexia and great reluctant to stand. The normal stance was altered to relieve the weight taken by the affected feet. In acute cases, if the fore feet where involved the horse would stand with the hind legs down under the body. The fore legs trust forward taking as much weight as possible on the heels. When only

the hind legs were affected the animal would shift its weight forward on the fore legs pulling them back under the body. If all four feet were involved the stance was not dissimilar to that of the fore feet except that the weight was taken as much as possible on the heels. Chronic laminitis was characterized by bands of irregular horse growth which were seen in the hoof close to the toe and diverging at the heel.

Gibbons (1964) reported that chronic founder in ponies was characterized by constant lameness, rotation of the pedis, dropped sole and penetration of the 3rd phalanx through the sole and abnormal wall growth.

Ackerman, Coffman, and Clement (1975) found that the feet affected with chronic laminitis were characterized by poor filling of the terminal arch, larger and loose numerous primary branches, and irregular vascular pattern in the corium of the hoof.

Adams (1974) discussed that horses suffering from chronic laminitis with rotation of the distal phalanx have a tendency to land on the heel followed by an exaggeration to slap.

Kuwano, Katayama, Kasashima, Okada, and Reilly (2002) recommended that as a complication of chronic laminitis, an abnormal horny structure called lamellar wedge, is generated between the hoof wall and the laminar epidermis. Suggesting it is on ectopic white line which is thought to be finally able to inhibit normal hoof wall growth. So that it should be resected at the optimum time when would be after one month from the onset of the disease.

Stick, Jann, and Scott (1982) found that all cases of laminitis required serial radiographs. They should be taken from 48 to 72 hours after the acute onset of laminitis to monitor the progress of rotation of the distal phalanx.

Hood and Johnson (1982) mentioned that it is beneficial to provide short periods of exercise (10 min / hour) for the first 24 hours. Exercise is considered most beneficial during

the acute onset of lameness, but it is contraindicated after digital pathology progresses because it increases the chances of mechanical separation of the distal phalanx from the hoof wall.

Adams (1987) advised treatment of the developmental phase of laminitis by mineral oil, which acts as bulk laxative and also coats the wall of the intestine. Mineral oil can be repeated at 4-6 hours intervals until all grain has been removed from the intestinal tract.

Under laboratory conditions, Hood David M., Connie K. Swenson, and A. Bruce Johnson (1981) found that heparin decreased the incidence of onset of lameness from 90 to 20% and non of the horses developed rotation. The recommended dose of heparin is 100 units/kg given I.V. four times a day and very slowly. Penury benzamine is an experimental drug that has been used successfully to prevent laminitis. It can be used at a dose of 2 mg/ kg divided into 2 doses, given at 12- hour interval to produce affected alpha adrenergic blockade for 72 hours.

Johnson (1982) reported that treatment of acute laminitis was activated by adrenal corticotrophic hormone (ACTH) because of its indirect effect on osmolarity.

Adams (1987) advised placing of horses in stalls with soft sand underfoot. This serves to support the ground surface of the sole and allows the horse to stand in a more comfortable position. Mares that developed laminitis were accompanied by prolonged diestrus. It is often beneficial to administer intramuscularly 10 mg of dinoprost tronethamine (Prostin F2 Alpha) to bring them in estrous. In some cases, laminitis symptoms disappear with the onset of estrus for mare that are in heat for prolonged periods with accompanying laminitis. Repositol progesterone (500 mg) or other appropriate drugs should be used intramuscularly.

Hood and stephans (1981) reported that arguments can be made for the use of hot and cold soaks. Since the foot is ischemic, the decreased temperature obtained with cold soaks should decrease the metabolic requirement for oxygen within the foot. Hot soaks, on the other hand, serve to vasodilate the vasculature within the foot and increase the capillary perfusion.

Annon (1966) found that the 1st aid treatment of acute laminitis includes the application of ice packs. The horse is taken off grain and put on a hay ration. A bar shoe applied to relieve pressure on the frog. In chronic laminitis a good hoof dressing is applied 2-3 times a week.

Mc Diarmid and Duff (1996) mentioned that the use of frog support has been well recognized for the treatment of acute laminitis and in some chronic cases of laminitis. A commercially available frog support has been used but both authors have experienced problems with these supports producing abrasion injuries over the bulbs of the heel.

The use of a roll of bandage fitted in place over the central sulcus of the frog is often used and does not appear to be associated with as many heel bulb abrasions (Eustace, 1992).

Allen, Foerner, and Gordon (1986) recommended that deep digital flexor tenotomy at the level of the mid pastern can be used effectually as a salvage procedure in horses with chronic refractory laminitis.

Walker and Geiser (1986) and Huntetal (1994) reported that treatment of laminitis in association with heparin administration, PVC is monitored 9.12 h and the heparin discontinued when PVC drops to 20 % or the risk of laminitis passes. Acepromazine or nitroglycerine paste is also concurrently administered for their vasodilative properties.

Moyer, (1980) mentioned that the basic principle of foot treatment in chronic laminitis includes trimming and shoeing to reestablish the normal alignment of the distal phalanx and hoof wall, and protecting the painful sole from pressure due to truma. Excessive hoof wall is removed. Additionally, it is helpful to thin from the ground surface proximal to decrease the pressure on this sensitive region. Both will reduce the rotation and tearing forces on the suspensory apparatus within the foot.

El-Baroudy (2005) reported that treatment of acute laminitis started as prophylactic when laminitis was suspected as in case of prolonged colic especially those associated with diarrhea. History and clinical signs were very important to determine the line of acute laminitis treatment.

Sand Crack :

O'connor (1965) defined sand crack as a fissure in the wall of the hoof, parallel to the horn tubules, commencing at the coronet and extending a variable distance down the wall. Sand crack is classified into, complete or incomplete, superficial or deep, straight or tortuous recent or old and simple or complicated. While, Jones (1986) classified sand crack into two categories, 1st one, crack which starts at the coronary band and eventually grows down to extend along the whole length of the wall. The 2nd, the crack begins lower in the wall and extends distally to the bearing surface of the hoof.

Adam's (1987) identified sand cracks as toe, quarter, or heel cracks depending upon their location in the hoof wall. It may occur in either the front or hind feet.

Hoof cracks are more frequently observed at quarters of the fore feet, and toe of hind feet. Most of the cracks were seen discharging a purulent exudates and animal showed sever degree of lameness. Occurance of cracks may be attributed to unequal distribution of weight on foot as well as the alternative moisture and dryness of the horn, excessive growth of the hoof wall causing a splitting of the wall. O'connor (1965), Jenny Evans and Raker (1965), El- Guindy (1981) and El- Sheikh (1992)

O'Grady (2001) mentioned that the most common recognized cause of quarter crack include, truma to the coronary band, pre-existing damage to the corium from infection and abnormal hoof conformation (especially the long toe, under run heel, focal foot imbalances, short shoes, abnormal landing pattern when the foot strikes the ground.

Although the causes of cracks mentioned were so numerous however, additional factor, such as white hoof walls subjected to drying and cracking that could not resist trauma as pigmented hooves (Adams 1987). Diet deficiencies in certain essential food nutrients were also considered as factors effecting the state of the horn. (McCunn, 1974)

Adams (1987) mentioned that the diagnosis is based on the presence of the crack, which is easily identified. Hoof tester can be utilized to verify that the pain resulting in the lameness is associated with the crack in the hoof wall. Perineural anesthesia can also be helpful. Bleeding from the hoof wall crack after exercise indicates that the crack has extended down to the sensitive laminae. Pus will exude from the infected hoof when pressure is applied.

O'connor (1958), Frank (1964), Jenny et al (1965), McCunn (1974), and Jacobson and Hayes (1978) attributed this affection to a wide variety of causes among which direct injuries of the coronary band occasioned by animal at fast work overreached, self infected treated with the calkin of an opposite foot as well as blows of any kind of accidental wounding.

Jenny, Evanse and Raker (1965) reported that treatment of quarter and toe cracks by exposing the full depth of crack with sharp knife. The wound area is thoroughly washed. Hemorrhage is controlled by absorbable cellulose preparation. The horn wall in either side of the crack is slightly under cut in order to provide a better mechanical support for filling material. On each side of the crack, several small holes are drilled through the horn wall. Through these holes umbilical tape is placed back and forth to minimize motion between the wound lips and provide a scaffold for subsequent application of the plastic material. A shoe made with a wide webbed branch also may be used with plastic window instead of the umbilical tape.

Evanse, Jenny, and Raker (1966) recommended that treatment have been aimed at stopping movement of the horn surrounding the crack. A crack will not heal from side to side but must be corrected by new horn growth from above. Horn growth at a rate of one third of an inch (0.8cm) per month. Recently a treatment which involves filling the hoof cracks with a

specially prepared self-curing adhesive acrylic in conjunction with umbilical tape lacing. Acrylic is supplied as white powder. A bar shoe that gives ample support to the quarter and heel should be used.

Hickman (1981) stated that treatment is directed to removing the pressure at the free extremity to immobilizing the edges of the crack. Deep and incomplete sand crack, are subjected to paring the edges of the crack and cleaning the underlying sensitive structures. The edges are brought together and immobilized by inserting sand crack clips. In superficial and incomplete crack. Two grooves are cut from the coronet in the form of a V shape to meet at the lower limit of the crack, two parallel grooves are cut on each side of the crack, from the coronet to the bearing surface. The grooves must be cut to the depth of the white line. The bearing surface of the wall immediately under a complete crack must be pared away to prevent any pressure at this point from the shoe.

Adams' (1987) reported that any type of hoof crack or hoof defect can be treated by the use of plastics epoxy glues fiber glass or special hoof repair material can be used. The crack must be thoroughly cleaned and undermined to hold the plastic in place. Another method of hoof crack repair is to use fiberglass patch and screws. Recently a new prosthetic hoof repair material 10 x has been developed, has a good adhesive qualities. Plastic are an excellent way to repair hoof cracks since they seal the crack and prevent infection of sensitive tissue.

Breningstall (1997) stated that methods of treating cracks depend on the type and location of the cracks due to the possibility of lameness or deep hoof problems. These includes, draw two clips, one on each side of the crack, and nail the shoe on the foot, (clips consist of metal drawn from, or added to outside edge of a shoe. They lay against the outside of the hoof wall.). When the shoe is nailed on, the clip should cover the crack on both sides and make contact with the hoof wall, staple the crack together with a hot staple and cover the crack with hoof repair kit. Drill holes on each side of the crack and lace with wire, put screws on each side of the crack and place with wire, use hoof repair kit with fiberglass matting cover with more hoof repair stuff, use a commercial hoof crack repair kit and support it with a shoe.

O'Grady (2001) mentioned that when infection is present, it is characterized by marked lameness, pain on palpation and a swollen, discoloured coronary band above the defect. Occasionally, exudates can be expressed when digital pressure is applied to the coronet. If infection is present the crack should be opened and bandaged with 2 % tincture iodine, or a similar disinfectant agent, for at least 48 h before the repair. Before beginning the quarter crack repair, the shoes should be removed and the feet trimmed appropriately. In horses with the long toe under run heel conformations an attempt to move the break over back is helpful .

Thrush :

Adams (1987) reported that thrush is a degenerative condition of the frog involving the central and lateral sulci. It is characterized by presence of black necrotic material in the affected areas. The infection may penetrate the horny tissues and involve the sensitive structures.

O'connor (1965), Johnson (1972) and El-Sheikh (1992) added that hind feet are more frequently affected than fore ones.

Fessler (1971) and El-Sheikh (1992) found that, an occasional case of thrush becomes complicated with deep involvement of the corium of the frog. Cellulitis of the digital cushion, and even necrotic tendonitis. They added that when destruction of germinal tissue occurs, granulation tissue must develop first and then becomes gradually covered with keratogenic tissue from the margins of the lesion.

Adams (1987) reported that, the predisposing causes of thrush are unhygienic conditions, especially when horses are kept in poorly managed stalls or poor foot trimming. Many organisms are probably involved, but *Sphaerophorus necrophorus* appears to be the most important of these. The signs reported were increased amount of moisture and a black discharge in the sulci of the frog. This discharge which varies in quantity has a very offensive odour when the affected sulci are cleaned. It will be found that they are deeper than normal and may extend into the sensitive tissues of the foot, causing the horse to flinch when they are

cleaned. Diagnosis is based on the odour and physical characteristics of the black discharge in the sulci of the frog.

Johnson (1972), and El-Sheikh (1992) stated that the most important therapy for thrush is to correct the poor sanitation and to trim the feet properly to allow frog pressure. Drying agents such as formalin applied topically to the area is sufficient for the treatment of early cases. Advanced cases will respond well to soaking in a supersaturated solution of magnesium sulfate under bandage. Systemic administration of antibiotics and bandaging with a bacteriostatic ointment is indicated .

Adams (1987) recommended that medication may be used include equal parts of phenol and iodine. (Tincture of iodine, and 10 % formaline) another treatment consists of packing the sulci with cotton soaked in 10 to 15 % sodium sulfapyridin solution.

Miller (2000) mentioned that treatment of thrush is a simple procedure. Thoroughly clean the foot, particularly the frog area and then treat daily with a basic bleach and water mixture. If the frog itself is damaged, all loose and dead tissue must be trimmed away.

Corn And Bruised Soles:

Johnson (1982) and Adams, (1987) defined corn as an involvement of the sensitive and insensitive tissues of the sole at the angle formed by the wall and the bar. Corns occur most frequently on the inner angle of the front feet and are rarely found in the hind feet. This may be due to the fact that the front feet bear more weight than the hind feet.

O'Connor (1965) and El-Sheikh (1992) mentioned that corns are very rare in unshoed feet. Fast work on the hard roads, wide spreading feet, leaving the shoes on too long are predisposing factors. Corns are very rare in the hind feet while they are very common in the fore feet.

Moyer (1980) and Adams (1987) found that corns are usually due to improper shoeing. When shoes are left on the feet too long, the heels of the shoe are forced inside the wall and cause pressure on the sole at the angle of the wall and the bar. It is a relatively common practice for farrier to bend the inside branch of the shoe toward the frog, to prevent pulling or stepping off the shoe.

Frank (1964) mentioned that the seat of the corn is the area where the lower edge of the lateral cartilages and the tip of the coffin bone pound down into a narrow, acute triangular formed by the wall of the hoof.

Adams (1987) discussed that, corn is an involvement of the sensitive and insensitive tissues of the sole at the angle formed by the wall and the bar. Three types of corn lesions may be evident, first one dry corn in which haemorrhage within the inner surface of the horn resulting from bruising of sensitive tissue covers red stains. Second one, moist corn caused by severe injury that results in serum beneath the injured horn. Third one is suppurating corn resulting in necrosis of the sensitive laminae of the palmer or planter aponeurosis.

O'Connor (1965) reported that, the treatment of the corn activated by removal of the shoe, pairing horn over the corn, the foot should be immersed in antiseptic bath for half an hour to one hour morning and evening when suppuration has extended upwards beneath the wall remove A shaped portion of the wall to ensure the scape of pus. An ordinary shoe or bar shoe with bar resting on the frog or three quarter bar shoe.

Puncture wound:

O'Connor (1965) mentioned that, puncture wound in the sole caused by the penetration of a nail or sharp. Pointed objects, as piece of iron, wood, bone, or the clip of a shoe. The point of entrance may be in the sole or frog but the bar is seldom penetrated.

Johnson (1970) reported that, puncture wounds or breaks in the sole are always associated with a black dot or line at the site of the initial injury. The penetrating object often

may be found still embedded in the sole, such occurrences are most common during dry periods when horses feet are dry. He added that, the most common sequelle to a puncture wound of the foot or breaks in the sole is a subsolar abscess puncture wounds at the white line will frequently drain at the comet above the puncture wound.

Also Johnson (1972) added that subnural abscess result from puncture wounds in the white line or cracks in the horny wall. In puncture wounds of the white line. Suppuration follows the line of least resistance.

Adams' (1987) stated that puncture wounds of the foot are quite common in horses, puncture wound in the middle third of the frog are most serious because of the possibility of puncture of the navicular bursa, puncture wounds of the sole may cause osteitis fracture and necrosis of os pedis.

O'connor (1965) advised that, for treating puncture wound in the sole, injection of antitetanic serum is indicated at once, thinning the horn round the orifice of the wound to facilitate the escape of discharge and allow antiseptic lotion to come into acid or pure creolin to destruct any bacteria. Afterwards protect the wound with an antiseptic dressing of iodoform. Immerse the foot for at least half an hour in a warm antiseptic bath. Removing the excessive formed granulation tissue with knife or by application of a caustic such as powdered sulphate of zinc perchloride of mercury or sulphate of copper or formaline (1 – 40) put a dressing of tar and cover with a leather or metal shoe.

Adam's (1987) recommended that, to treat a puncture wound drainage of the lesion is indicated. The region is kept clean, and protected until healing occurs. An antiseptized boot can be used in place of bandaging soak the foot daily in a magnesium sulphate, flushing with 1 % povidine iodine solution 2 to 3 days and bandaging every day. Navicular bursa require drainage through the center third of the frog. Involvement of coffin joint treated by tranquilization and 500 to 1000 ml of sterile salt solution should be flushed through the joint and systemic antibiotic which are continued for 2 to 3 days. If no improvement the coffin joint

should be opened surgically and drained. A distal oblique hole is drilled through the hoof wall to provide ventral drainage, flushing with antiseptic until infection is controlled, systemic antibiotics for 15 to 21 days. Once the lesion is completely dried a shoe with a full pad can be applied.

Quittor:

O'connor (1965), Johnson (1982), McCunn (1974) and Adams (1987), defined quittor as a chronic purulent inflammation of the collateral cartilages of the third phalanx characterized by necrosis of the cartilage and sinus drainage through the coronary band. They attributed the cause to injury followed by infection at the coronet involving the collateral cartilages occasioned by severe wire cuts, calkins, treads or interfering on the other hand they reported that it might be secondary to penetrating wounds through the sole or suppurated corns.

Also O'connor (1965) described that necrosis of the skin in the affected region as a result of the combined effects of cold and septic mud from which the infection could spread subsequently to the cartilage.

Adams (1987) found that Quittor was most commonly located in the fore limbs and McCunn (1974) observed that it is more common in drought horses, but not frequent in light horses.

Canker:

O'connor (1958), Frank (1964), Johnson (1982) defined canker as a chronic hypertrophic moist eczematous dermatitis usually begins at the frog and extends to involve the sole and wall. Adams (1987) defined the disease as a chronic hypertrophy of the horn producing tissues of the foot. The affection is more seen in the hind feet, it may involve any one or all feet. Lameness evidenced in advanced cases together with the characteristic foetid odour and the chronic vegetative growths of the sensitive tissue are diagnostic. The frog which may be intact has a ragged appearance and its tissue loosens easily, and when removed,

reveals a swollen corium covered with very penetrating offensive odour and oozing whitish caseous exudate.

McCunn (1974) stated that the specific cause of the condition was not exactly known however, different species of bacteria and spirochetes were isolated from affected tissues. He added that bad hygienic conditions in animal enclosures especially the presence of muddy stand containing bedding saturated with faeces and urine, improper care of the feet as well as atrophy of the frog seemed to favour the onset of canker.

Adams' (1987) advised that treatment canker by removing all loose horn and affected tissues and antiseptic, astringent dressing applied. A 5% picric acid solution should be applied under the bandage. Caustic agents, such as a mixture of copper sulphate and zinc sulphate crystal, are sometimes used. Mason (1962) added that penicillin was used at the rate of 3 million units intramuscularly per day until improvement was shown. Then a similar dose was given every second day until the condition was nearly cured after which the treatment was administered every third day.

Sidebone:

Johnson (1982) and Lunduall (1965) defined sidebone as an ossification of the collateral cartilages, which are usually found in the forefeet and are most common in horses having poor conformation. The condition is not common in thoroughbreds.

Adams (1987) described that, Radiograph will reveal that the cartilages have partially or completely ossified after ossification stops. There are usually no signs of lameness, although the involved cartilages no longer function in the normal physiological process of the foot.

The same author advised that if the side bone is definitely the cause of lameness, the quarters may be grooved or thinned. This permits expansion of the foot and relieves the pain.

The horse should be shod with full roller motions shoes to decrease the action in the distal interphalangeal (coffin) joint region.

Lunduall, (1965) added that when fractured sidebones cause more acute signs of lameness, small sidebones cause more acute signs of lameness, small proximal chips can be removed, but large fractures should not be surgically removed. If the fragment involves the proximal end of a sidebone, it can easily be removed by surgical incision over the area.

Seedy toe

O'connor (1965) described that, seedy toe is characterized by separation of the wall from the subcorneal tissue; and the formation in the inerspace of crumbly pumice stone like horn secreted by the sensitive laminae. Also added that, the condition would appear to be the result of a chronic local laminitis following traumatic injury such as might be caused by a toe-closely driven nail, wide spreading feet are most subjected to it.

Shuttleworth (1966) Awad (1967) and Bolbol and saleh (1987) reported that, seedy toe cases were recorded in about 7.4 % of the hoof affections. About 92 % of cases were donkeys in which the fore limb was affected in 88.5 % of cases seedy toe was mostly seen in unshoed donkeys working in farms.

O'connor (1965) advised that, treatment of seedy toe by removing the new formation of horn to diminish the pressure on the sensitive structures. Then packing the cavity with tar and apply a shoe having no bearing on the affected region and leather sole to keep the dressing in position. A bar shoe with a breach in the iron apposite to the affected part is suitable. Application of blister on the coronet will promote the growth of normal horn.

Jenny et al (1965) mentioned that, the classical treatment of seedy toe consists of removing the crumbling material between the wall and the laminar corium, when there is extensive separation between area undermined wall. Plastic hoof repair material could be applied.

pedal osteitis

Lundvall, (1969) defined that pedal osteitis as demineralization of the distal phalanx resulting from inflammation. It usually manifests itself radiographically as roughening of the solar borders of the distal phalanx. Although the problem may be found anywhere in the distal phalanx, it is usually confined to the toe and wing regions of the front feet.

Adams (1987) mentioned that the main cause of the disease was persistent inflammation of the foot, due to numerous factors, which may cause rarefaction of the distal phalanx as chronic bruising of the sole, persistent corns, laminitis, puncture wounds and other inflammations over a long period of time..

Also, Waters, Lebel, and Park (1969) added that nutritional and heritable causes were considered. Lameness leading to disuse osteoporosis has also been developed

Rendano and Garnt, (1978) recorded that it is difficult to diagnose pedal osteitis on radiographic examination. The degree of roughening can also vary from the medial to lateral, and the lateral border usually appears to be more roughened when a variation exists oblique projections are recommended to adequately the lateral medial solar border of the distal phalanx. Therefore, the diagnosis of pedal osteitis should be made only when physical signs concur with the radiographic findings.

Adams, (1987) advised that treatment of this disease is dependent upon the cause. Shoeing may help by keeping the sole away from the ground and preventing pressure on it. Pads of leather or Neolite under the shoe also may be helpful, as may padding of retread rubber or silicone rubber covered by a full pad of plastic or leather.

Hyper granulation tissue:

Frank (1962) and Fessler (1971) mentioned that, horses are frequently affected with minor lacerations and superficial abrasions of the coronary band region, bulbs and skin below

the fetlock. If severe injuries are neglected in anticipation of spontaneous exuberant granulation in the foot region is resistant to conservative treatment.

Adams (1974) founded that, equine sarcoid is a recurring granulation tissue that affects equines; sarcoid is most common following wounds of the lower part of the limbs. It is usually characterized by a raw granulation surface, that is somewhat mushroom shaped or as a wart like growth. Histologically it is characterized by irregularly arranged fibroblasts with larger nuclei. Etiology has been definitely proven to be virus.

Jones (1986) reported that, wire and sheet metal of the pulp are common objects to injuries. When these wounds are left untreated or not adequately bandaged, granulation tissue forces the cut edges apart and distorts the heel.

Burrows (1938) observed that, keloid is a sample of exuberant granulation followed a minor wire cut. Treatment is advised by the use of powdered alum, slaked lime, white arsenic. Zinc chloride and several cancer pastes.

Frank (1962) reported that, exuberant granulation tissue may be removed in a number of ways. If there is only small amount present it may be removed by applying copper sulphate powder and bandaged, left on for 24 hours, when the bandage is removed a thin layer of granulation tissue is removed and hydrochloric acid and sulphur should be applied. Vaseline should be applied to the normal skin around the area before the eschercotic paste is applied to the exuberant tissue.

Fessler (1971) recommended that, exuberant granulation in the foot region is resistant to conservative treatment. Caustics and wound powders frequently cause additional proliferation and may result in debilitating cicatrix formation so surgical management is required in most cases.

Adams (1974) advised that equine sarcoid should be surgically removed and the base cauterized by electrocautery to control haemorrhage. The sarcoid area should be kept clear and all hair shaved away from the wound every ten days to two weeks. Corticoid ointment containing antibiotic is applied to the surface of the lesion and a pressure bandage applied using conforming gauze and elastic tape until the wound is healed. The bandage is changed at intervals of 2 to 3 days. He added that one of the most successful methods of treatment for sarcoid is wide surgical excision.

Harle (1985) mentioned that initial management of pastern or heel laceration to prevent granulation formation should be done. A pressure bandage should be applied to control haemorrhage and local anesthetic is indicated. The wound is cleaned and a dressing is applied. Cast application is recommended in all but the most minor laceration the cast is removed in 2-3 weeks after which caustic powder is sprinkled on the wound, and a bandage is applied for another 3-5 days.

Jones (1986) recorded that, surgical treatment of exuberant granulation was done by wedge shaped excision of the granulation tissue so that the two sides of the wound can be reasonably apposed. This procedure may have to be repeated once or twice and skin grafting should be considered to hasten healing.

Inflammation of coronet:

Runnells (1967) Defined coronitis as inflammatory condition of the skin and underlying structures of the coronet.

O'connor (1958) stated that the etiology was often obscure, but it might result from repeated injury or irritation of coronet occasioned by self inflicted tread or other animal tread. He added that coronitis might be due to nutritional defects or parasitic infestation and most commonly met within light horses doing fast work. Asses and mules in which the toe and quarters are narrow were frequently affected.

However, O'connor (1988) added that there might be a hereditary predisposing of a rheumatoid nature or it might accompany some skin diseases or be associated with febrile condition.

Hoof deformities

Annon (1966) stated that, there are six common faults of foot conformation which include, base wide, base narrow, toe out, toe in, long pastern and short pastern. Base wide horses tend to toe out, base narrow horses tend to toe in.

Adams (1987) classified abnormal conformation of the foot to flat feet, in which lacks the natural concavity in the sole, dropped sole or pumiced foot in which the sole is flat and has no concavity, contracted foot or contracted heels in which the foot is narrower than normal and usually accompanied by a dished sole or an increased concavity of the sole, unilateral contracted foot which is congenital. Brittle feet ensue as complication of toe or quarter cracks. Bull-nosed foot, a foot that has been rasped down in front to fit the shoe, and coon-footed, the pastern of the coon-footed horse slopes more than does the anterior surface of the hoof wall.

Hoof deformities depend upon the nature of work of the animal, hoof care, chronic affection, and hygienic measures as well as nutritional deficiency. Therefore, the reported morphological changes within the hoof in horses may be due to all mentioned factors collected with each other or otherwise one of them produce such grave pictures of hoof deformities.

Certainly clinicpathological changes and disturbance in the dynamics of the digit are also considered. (Lambert 1966, Emmery, et al 1977, Ahmed 1979, Ahmed, Soliman1989 and Barakate 1989).

Soliman (1989) reported that, it had been found that hoof deformities in donkeys could be attributed to persistant standing of these animals in a confined housing without any work or even mild exercise, beside neglecton of trimming of their hooves for several years. Moreover

variation in the affected ration to these animals may also play a role in the affected ration to these deformities. He added that, according to the morphology of the hoof deformities it could be classified into the following patterns. Old elongated hooves ,at this form the animal walks on the heels for long duration .

Annon (1966) recommended that, the hoof should be cleaned and trimmed regularly every 4-6 weeks .he added that ,hoof trimming should be started at one month of age .

Fracture of the third phalanx

Scott, Mcdole and Shire, (1979), Weaver (1969) and Yovich Hilbert and Mcgill (1982) stated that fractures of the distal phalanx are not common. When they do occur the injury is usually associated with exercise on hard tracks, and the fore feet, particularly the left forefoot, appears to predispose in horse racing counter clockwise.

Adams (1974), Dubs and Nemeth (1972) Duncan and Dingwall (1971) Febble (1973) Haynes and Adams (1974), Hickman (1964), Pettersson (1972) mentioned that trauma is regarded as the primary cause of fractures of the distal phalanx, other factors such as stone bruises, hard surfaces, improper shoeing, infectious condition and nutritional deficiencies have been incriminated. It is felt that the palmer process fracture affects the lateral left that the palmer process fracture affects the lateral left forelimb and the medial right forelimb because of selective trauma to these regions during counter clockwise racing. On the other hand, midsagittal fractures of the distal phalanx are thought to result from external trauma to the hoof from kicking solid objects or when the foot lands on an unyielding object.

Johnson (1982) and Adams (1987) recorded that fractures of the perimeter of the distal phalanx generally only cause lameness for a period of about 2 to 3 weeks after which the horse may remain sound if shod with pads if the fracture is at the tip of the distal phalanx, the opposite foot should also be radio graphed as well.

Knuckling over

O'Connor (1965) reported that, knuckling at the fetlock is due to retraction or contraction or shortening of the flexor tendons. This deformity must be considered separately in young animals, in aged or adult subjects. In young animal most frequently congenital, but may be acquired within the first three or four years of age. The animal shows one of the degrees of knuckling, the phalanges are almost vertical. A perpendicular let fall from the front of the fetlock strikes the front of the hoof, or the perpendicular reaches the ground in front of the hoof, or complete flexion of the affected joint or joints. In adult subjects, excessive volar flexion of the phalangeal joints may be due to cicatricial contraction of the tendons following chronic tendonitis or shortening of these structure may be secondary to other lesions, such as ringbone or diffuse osteo-periostitis of the pastern, chronic synovitis, dry arthritis of interphalangeal joint, corns, or contracted foot. All these conditions interfere more or less with the normal support of weight on the limb causing the fetlock to assume a permanent degree of flexion.

Plakhotin (1966) observed that, complete laceration of the deep digital flexor tendon is accompanied by dislocation of the coffin joint, and the animal rest on the heel portion of the hoof. As both digital flexors and interosseal muscle lacerated the support is nearly on the whole flexor side of the toe, and as extensors are lacerated, on the dorsal side.

O'Connor (1965) mentioned that, the aim if treatment of knuckling at the fetlock, in young animals is to get the toe of the foot, at least, to bear weight. Splints or a plaster of Paris bandage may be required to maintain the foot in this position, a soecial shoe may be applied which tends to throw the fetlock back into position. In slight cases it is sufficient to lower the heels and put on a shoe with the toe thickned and projecting in front. In more pronounced cases Friebel's apparatus is indicated, occasionally a case is met with in which the fetlock remain s fixed in the flexed position after cutting the tendons. He added that in adult animal treatment consists any adopting measures appropriate to the cause. A long toed shoe may be useful in correction the condition.

Navicular disease

O'Connor (1965) reported that, navicular disease is due to chronic osteitis of the navicular bone, associated usually with chronic synovitis of the navicular bursa. The most noticeable change in the navicular bone is the presence of ulcers on its tendinous aspect. The first symptom appeared was the horse pointing his foot when at rest. Both feet are usually involved so, the animal points them alternately, going on the toe, seat of lameness appears to be the shoulders. He added that, the local symptoms comprise the alterations in the form of the foot which becomes boxy, that is contracted and high at the heels with very concave sole.

Ackerman, Johnson, and Dorn (1977) stated that navicular disease begins as an inflammation of the bursa between the navicular bone and deep flexor tendon, and may progress to the flexor surface of the bone. These erosions may appear around the navicular ridge on the bone. These erosions may appear around the navicular ridge on the flexor surface of the bone as elliptic defects having sloping walls and dull granular reddened floors. They added that, navicular disease was seen in horses ranging 3-15 years of age. The same authors reported that, 22 % of all navicular disease cases were diagnosed in horse 4-15 years of age, 68 % all navicular disease cases were in males.

Adams (1987) recorded that, navicular disease affecting fore limb in horses between 4 and 15 years of age. The syndrome has been shown to have hereditary predisposition classically the condition has been described as a chronic, progressive degenerative disease affecting the navicular bone, navicular bursa, and flexor tendons. Diagnosis of navicular disease depends on history of intermittent lameness, stumbling and choppy gait. Hoof tester will elicit pain on pressure over the central third of the frog. After performing a suitable nerve block, radiographs should be taken with careful examination (Annon, 1966).

El-baroudy (2005) reported that diagnosis of navicular disease based on history intermittent lameness that decreases during rest. This agrees with the inspection of show jumper horse walking or trotting through lameness evaluation, with short limb stride, tends to

land on the toe and may occasionally stumbles. Our attention was focused toward navicular disease.

O'Connor (1965) stated that veterinarians of the old school claimed that they cured navicular disease by bleeding from the jugular vein, purgation, applying poultices to the feet, and by giving prolonged rest. Also by the insertion of a frog seton passed through the plantar cushion from the hollow of the heel to the point of the frog just behind the plantar aponeurosis, and left in position for about three weeks and cleaned daily. Its object being to favour union between the navicular bone and perforans tendon. Grooving the contracted hooves and applying light shoes is said to have a good effect, also double plantar or median neurectomy is necessary.

Ackerman, et al (1977) classified the treatment of navicular disease as surgical or medical. Surgical treatment consisting of bilateral palmar digital neurectomies. Medical treatment consisting of systemic injection phenylbutazone or orgotein combined with corrective shoeing.

Jones (1986) recommended that, there are three main categories of treatment of navicular disease. First is reduction or abolition of pain. Second, drugs which affect the blood supply to the navicular bone and the third one, hoof trimming with corrective shoeing. Pain alleviation using two non-Steroidal anti-inflammatory drugs, phenylbutazone and meclafenamic acid. Intra-bursal injection of cortisone preparation is practiced by some workers. Neurectomy is the earliest form of treatment for navicular disease, initially the lateral and medial palmar nerves sectioned. He added that, drugs which affect the blood supply include warfarine and isoxuprinhydrochloride. Warfarine reduces blood viscosity and affects red blood cell morphology, dose 0.018 mg/kg (10 mg for an average horse) and increasing the dose by 20 % increments until the desired effect is achieved final dose rates are variable from 0.012 – 0.75 mg/kg for seven weeks. 1mg/kg of vitamin k should be given I.V. A. double-blind trial in which isoxusprine hydrochloride in paste form in dose rate 0.6 mg/kg body weight for 1st 3 weeks of treatment. If there is no response then a higher dose rate of 0.9 mg/kg

and even 1.2 mg/kg may be used without side effects for a further three weeks. A second course of isoxuprine hydrochloride administered over 6-8 weeks. The only published contraindications are that the drug should not be administered to pregnant mares, within 14 days post partum or after recent arterial haemorrhage. Finally corrective trimming should be aimed

Adams (1987) selected the treatment for each type observed of navicular disease. In early acute phase, rest and administration of non steroidal anti-inflammatory drugs. Corrective shoeing consists of raising the heels by building them up, rolling the toe, and using a bar across the center one third of the frog. Periodic administration of non steroidal anti-inflammatory drugs, such as phenylbutazone, meclofenamic acid, naproxen or flunixin meglumine. Local or intrabursal injection of both steroids and orgotein has been recommended. Injection of the navicular bursa with irritants such as lugol's iodine, has been described in some of the older literature. An alternative treatment is anticoagulant therapy, dicumerol can be administered per os daily at rate of 0.018 mg/kg body weight. Recently a peripheral vasodilating agent isoxsuprine hydrochloride has been used as a medical treatment in a dose of 0.6 mg/kg body weight two times a day for six to seven weeks.

Denoux Thibaud, Riccio, (2003) advised that tiludronate efficacy is demonstrated in the treatment of navicular disease at the dose of 1mg/kg but another designed a double blind, placebo controlled clinical trial to compare two doses of tiludronate, 0.5 mg/kg and 1 mg/kg but administered via daily intravenous injection over 10 days for the treatment of navicular disease. He found that horses treated with the higher dose showed optimal improvement of lameness and return to normal level of activity 2-6 months post treatment. The more recent the onset of clinical signs at the time of treatment, the greater the efficacy. The treatment did not modify the response to extension and flexion tests. The lower dose failed to significantly improve the condition. Tiludronate efficacy is demonstrated in the treatment of navicular disease at the dose of 1 mg/ kg B.w.

Eliashar, meguigan, Wilson, (2004) founded that collapsed heels conformation has been implicated as causing radical biomechanical alterations, predisposing horses to navicular disease. Hoof conformation has a marked correlation to the forces applied to the equine foot. Hell collapse, ad defined by the change in hell angle in relation to toe angle appears to be inaccurate parameter. The forces applied on the foot are well correlated to the changes in the ratio of heel to toe heights and the angles of the distal phalanx.

El-Baroudy (2005) reported that the treatment of navicular disease was non steroidal anti-inflammatory drugs. For pain management, corrective shoeing by elevation the heels to reduce the stress on the palmer aspect of the feet and tension on the deep digital flexor tendon. Isoxsuprine to produce peripheral vasodilation . Inter-articular and IV hyaluronan as well as IM injection of PSGAG were also used in treatment. Many of these therapies, usually in combination were successful in managing this disease.

Materials and Methods

A number of **823** animals of equine species aging 2-15 years old of both sexes, were examined during the period from 2001 to 2006. These animals included (497 horses, 242 donkeys and 84 mules). They were suffering from different degrees of lameness due to various hoof affections.

Table (1) showing sources and number of examined animals:

Animal source	Animal number			
	Horses	Donkeys	Mules	total
*Army sport clubs in Cairo and Alexandria.	179	-	-	179
*Principle Veterinary hospital of the army	50	-	-	50
*Brook hospital for animal clinic in Alexandria.	248	169	52	469
*Vet. Clinic Faculty Vet. Med., Alex. University.	20	73	32	125
Total	497	242	84	823

Each animal was subjected to the following protocol for diagnosis of the hoof lesion:

(1) Case history:

Case history was collected from rider, trainer or owner.

(2) Clinical examination:

Pulse, respiration , and body temperature.

1- Inspection:

Carried out by gait during walk, that, canter and longing in both directions.

2- Aid of instruments:

Wooden hammer, hoof tester, hoof knife and hoof curette to detect the seat and the nature of the lesion.

Hoof tester was used for diagnosis by inducing solar or frog pain for diagnosis of laminitis or navicular disease, respectively.

3- Digital pulsation:

Increase or decrease in the palmer digital pulsation indicating the state of foot circulation.

(3) Radiographical examination:

Radiography was an important part diagnosis and evaluation of lameness. It was the most important role to give information about bones and joints. The type of x-rays machines were used in this study.

Portable machine:

ACU. RAY HF manufactured by Sterne manufacturing, Canda.

Maximum peak output 100 KVP.

Maximum tube 30 MA.

It was used mainly for cases belonged to stable forms and clubs. The length of extension cord was long to help with the proximity of the examination area. Also, stabilizer was used to fix the fluctuations in line voltage on the farm.

Treatment of hoof affections was performed by one or more of the following:

(1) Corrective interference:

The foot was inspected for signs of cracks, discharge, abscess, thrush and improper shoeing. Special notes were made to show how it lies on the land.

Corrective interference included:

- Trimming of the foot with application of special medicine.
- Applying specific shoe.
- Adjusting the excessive shoe contact with the sole to remove the extrapressure.
- Removal of disintegrated material.
- Hoof curette and rasping until the hoof takes its normal shape.

(2) medical interference :

Each case had special medical and /or surgical treatment according to the nature of the lesion.

Animal control and anaesthesia :

Physical and /or chemical restraint of animals were carried out according to each case. Local, regional, or even general anesthesia were also performed when the condition necessitated .

The following drugs were used for anesthesia:

- 1-Rompon 0.1mg/kg . I.M. (bayer merk leverkusin, W.Germany)
- 2-Combelen 3mg/kg. B.W. I.V. . (bayer merk leverkusin, W.Germany)
- 3-Procaine adrenaline was used as local infiltration anesthesia around the site of operation (Misr for medical pharmaceutical preparation)

The following drugs were used for treatment:

Velosef	Cephadrine	4gm /100 kg I.V	Esquib
Flunixin meglumine	Finadin	1mg/ kg/ 12- 24h	Schering plough
Nitro furazone	Furaseen	As required Orally	Chemipharm

Phenyl butazone ^h	Phenyl butazone	2.2 mg / kg		Butler
Avil	Pheniramine	1 mg / 50 kg I.V		Aventis
Streptopencid	Streptomycine	2 gm/ animal		Cid co.
Methionine		1gm/animal		
Cupper sulphate	Koper tox	As required	Local	Welkam-Egypt
Sulphonamide powder	Sulphonamide powder	As required		Misr. Co
Polyvinylpyrrolidone	Betadin	As required	Local	Nile Co.
Metacresol	Sulphonic acid and Formaldehyde	Albothyl	BYK	Gulden Konstanz
tincture iodine	antiseptic			
Medical tar	topical application		ointment	
Cod liver oil	topical application			

(1) Surgical interference:

Surgical instrument set used during surgeries:

Towel forceps, curved mosquito hemostats, straight mosquito hemostats, straight Kelly forceps operating scissors ,curved scissors, straight scissors needle holder, Right angle forceps, No.3 scalpel handle, No.4 scalpel handle, needles.

Surgical techniques :

All surgeries were done under anaesthesia as in table (2)

1-Palmer digital neurectomy :

The horse was dorsally recumbent under general anesthesia Two incision 3 cm just dorsal to lateral and medial edges of superficial deep flexor tendon starting just below the base of the sesamoid . The nerve is gently stretched and transected using scalpel blade as far distally and all transected nerve grasped dorsally, separate the nerve sheath from the nerve, transected the nerve, ligation to nerve sheath to avoid neuroma.The incision is closed in a single layer.

2- Sand crack:

Pairing and thinning the fissure from the two edges in order to decrease pressure on the sensitive tissue, filling the gap with medicated tar. Blistering the coronary region by iodide of mercury and applying a pressure bondage in case of toe crack drill hales in each side of the

crack and thread holes with stainless steel wire. Application of sulphonamide powder above and inside the crack.

3- Thrush:

Using hoof knife, removing of all desentigrated horny material of the forg and sole was carried out. Washing the frog and sole with 5% cupper sulphate and local application of kopertax. In more advanced cases, systemic injection of streptopencid intramuscularly daily 1 for five sauccessive days in a dose of 2 gm/animals. Also using equal part of phenol and iodine 10% formaline als used topical application of nitro furazone ointment.

4- Seedy toe:

Seedy toe was treated by widening the separated portion and curetting, to thing with tincture iodine and filling the space with gauze immersed in medicated tat. Gauze was changed several times until healthy tissue was achieved.

5- Hypergranulation tissue:

Surgical manipulation of the hypergranulation tissue was carried out by excision of abnormal tissue, washing with Betadin, cauterization of the area using Albothyl with local application of sulphanamide powder. Lastly, tying the lesion with pressure bandage.

6- Corn:

The first aid of treatment in all cases of corn was pairing and thinning of the horny layer of the sole around the lesion until the healthy tissue was exposed.

7- Quittor:

surgical excision of collateral cartilage is dose just dorsal to the coronary band over diseased collecteral ligament sakry the hoof in time iodm, flushing Betadine.

8- Elongation of the hoof:

All horses, donkey and mules which had hoof deformities with elongation were corrected by hoof curette and rasping until the hoof took its normal shape.

9- Side bone:

Excision was made through skin and connective tissue to the fragmented portion of bone. Dissecting the fragment. Then subcutaneous tissue and skin well sutured. A pressure bandage was applied for 2 weeks. Local application of penicillin ointment.

10-Tumor of the hoof:

Surgical removal of the abnormal growth under local anaesthesia. Parallel cuts are made in the hoof wall on either side of the tumour, and the section of hoof wall is carefully prised away from the underlying sensitive laminae up to the level of the coronet. The surgical wound is then packed with sterile gauze soaked in antiseptic solution (dilute povidone iodine) and the foot is bandaged.

11- Knuckling over:

Tenotomy of the deep digital flexor tendon under the effect of ring block using 2% lidocaine HCl at the middle of metatarsal region. Plaster of Paris bandage (Gypsona) was used after surgery.

12- Navicular disease:

Treatment of this case was corrected by bilateral palmar digital neurectomies.

Table (2) : Showing some information about drugs used among the study under observation:

Commercial name	Scientific name	Company	Form	Administration	Dose	Function
Rompun	Xylazine Hcl	Bayer merk Leverkusen (Solution 2 %	I.V , I. M.	0.1 mg / kg B.W	Sedative analgesic and
Combelen	Procaine adrenaline	Bayer merk Leverkusen)	Solution	I.V	3mg/kg	Sedative
Procaineadrenaline	Procaine adrenaline	Misr	Solution	Local	As required	Sedative
Velosef	Cephadrine	Esquib	Solution	I.V , I. M.	4 gm /100 kg	Broad spectrum antibiotic
Streptencid	Streptomycine	cid co.	Solution	I.M.	2 gm/ animal	Antibiotic
Furaseem	Nitro furazone	Chemipharm	Ointment	Soluble dressing	As required	Topical antibacterial for wounds
Finadin	Flunixin meglumine	Schering plough	Solution	I.V , I. M.	1 mg/ kg/ 12- 24ht	Anti inflammatory
Phenyl butazone	Phenyl; butazone	Butler	Tablet	Orally	2.2 mg / kg	Anti inflammatory
Avil	Pheniramine	Aventis	Solution	I.V I.M.	1mg /50 kg	Antihistaminic
Carbacol	Carbacol	Misr. Co	Solution	s/c	2 ml/animal	
Methionine	Methionine	Nile Co	Powder	Orally	1gm/animal	Additives
Kopetox	Copper sulphate	Welkam	Powder	Local	As required	Chemical cautery
Sulphonamide	Sulphacomound	Misr. Co	Powder	Local	As required	Chemotherapeutic
Betadine	Polyvinylpyrrolidone	Nile Co	Solution	Local	As required	Antiseptic
Albothyl	Metacresol sulphonicacid formaldehyde	Nile Co	Solution	Local	As required	Disinfectant

Results

The study under observation revealed that both sexes of equine species (horses, donkeys, and mule) were involved with hoof disorders (table, 3).

Diagnosis of 823 limb disorder in this study was based on clinical examination by inspection gait and using instrument confirmed by radiography.

497 Horses aging (2 – 15) years old, 242 donkeys aging (2-10) years old. Were affected with different forms of hoof disorders. Recorded cases include male and female. Also 84 mules were affected.

In this study 207 animals were suffered from laminitis. 90 of these animal had **acute form of laminitis** presenting 49 horses (28 male, 21 female), 29 donkey (17 male, 12 female) and 12 mules . The disease occurred with a history of over feeding with high concentrated ration. The horses showed typical attitude where the hind feet are carried up farther forward. The fore feet, were extended cranially in (Fig.,1).

Hooves palpation of the hoof in acute laminitis revealed presence of hotness over the wall and coronary band, at the same time increase of palmer digital pulsation was detected. Pain reflex, when hoof tester applied to the solar aspect of the hoof was evident by different degree.

Horses intended to treatment in the acute phase, were kept in wide box, with sand bedding. The animals were given phenylbutazone 2.2 mg/kg every 12-24 hours orally associated with flunixin meglumin 1 mg/kg every 12-24 hours I.V. for 3-5 doses according to the severity of the case. 72 cases of acute laminitis were cured within a period of 10-15 days and the animals took their normal posture.

Table (3): Showing frequency and percent of hoof disorders in male and female in equine species :

Hoof disorders	Horse			Donkeys			Male		Total	%
	M	F	Total	M	F	Total	No	No		
	1 Acute laminitis	28	21	49	17	12	29	12		
2 Chronic laminitis	41	23	64	21	16	37	16	16	117	14.22
3 Sand crack	50	34	84	27	19	46	17	17	147	17.86
4 Thrush	49	33	82	18	15	33	13	13	128	15.55
5 Seedy toe	66	24	90	20	13	33	16	16	139	16.88
6 Hypergranulation tissue	3	2	5	2	2	2		7	7	0.85
7 Corn	17	8	25	9	8	17	4	4	46	5.59
8 Quittor	2	4	3	1		1			4	0.49
9 Canker	3	1	4						4	0.49
10 Inflammation of coronet	4	2	6	2	1	3			9	1.09
11 Elongation of the hoof	7	9	16	6	3	9			25	3.04
12 Puncture wound	33	21	54	17	11	28	6	6	88	10.69
13 Side bone	2		2						2	0.24
14 Pedal osteitis	2		2						2	0.24
15 Turner of the hoof	1	2	3	1		1			4	0.49
16 Knuckling	1	2	3	2		2			5	0.61
17 Navicular disease	3	1	4	1		1			5	0.61
18 Fracture of the phalanx	1		1						1	0.12
Total	31	3	184	144	98	242	84	84	823	100.0

Chronic laminitis was met with in 117 animal which were 64 horses (41 male, 23 female), 37 donkeys (21 male,16 female) and 16 mules . Animals showed that the space between the rings at the heel are wider than those at the toe as in (Fig.,2).

Chronic cases were diagnosed radiographically by rotation of the distal phalanx which identified by divergence of the bone in relation to the hoof wall as in (Fig.,3 and 4). Chronic cases were corrected by rasping and application of leather shoe as in (Fig.,5) and application of bar shoe as in (Fig.,6). However these hooves did not return back to their normal size and shape. Administration of phenylbutazone in a dose of 2.2 mg/kg for 8 days. Was helpful.

Methionine were given in the feed with dose 10 gm per week then 5 gm per 4 weeks.

In this study no cases of laminitis were detected under 5 years and the highest percentage was at the age ranged from 6 to 12 years.

. In the present work 147cases showed different type and degrees of **sand crack** including 84 horses (50 male and 34 female), 46 donkeys (27 male and 19 female), and 17 mules. The affection was found affecting the quarter of the wall in thoracic limbs and the toe of the pelvic limbs.

Cracks originated from the coronet and extended downward as in (Fig.,7). An exudate under the crack and suppurative inflammation of the laminae were present in 25 cases as in (Fig.,8). Also cracks starting at the bearing surface of the wall and extending to a variable distance up the hoof wall were recorded in 42 cases as in (Fig.,9 and 10). From the 143 cases there were 67 cases in the quarter region and 76 at the toe region.

Complicated Sand crack diagnosed by hoof tester indicates that the crack has extended down to the sensitive laminae. Sand crack was treated according to location. In case of toe crack, after cleaning crack, drill holes in each side of the crack and thread the holes with stainless steel wire as in (Fig.,11). The cracks were recovered five months following the surgical interference.

In the present study 128 cases included 82 horses (49 male, 33 female) , 33 donkeys (18 male, 15 female) and 13 mules were met with disintegration of the frog manifested by exudation from the frog varies from slight dark color to black color as shown in (Fig.,12) all cases were diagnosed as **thrush**. Hooves of the pelvic limbs were mostly affected with thrush and the animal had no lameness. All cases were found standing on bedding mixed with urine and faeces.

Out of the 123 cases of thrush infection was noted penetrating the horny tissues and involving the sensitive structure as shown in (Fig.,13).

The first procedure in treatment of thrush was to correct the poor sanitation, removal of shoe, trimming of the feet and removal of unhealthy tissue as in (Fig.,14).

43 cases were treated by using equal parts of phenol and Iodine, 38 cases were treated using 10% formaline and 42 cases by 15% sodium sulphapyridin powder with local application of nitrofurazone ointment

All cases of thrush responded to the applied treatment within a period of 15 – 20 days. The cases treated with sodium sulphapyridine powder responded more quickly within 10 days (Fig.,15).

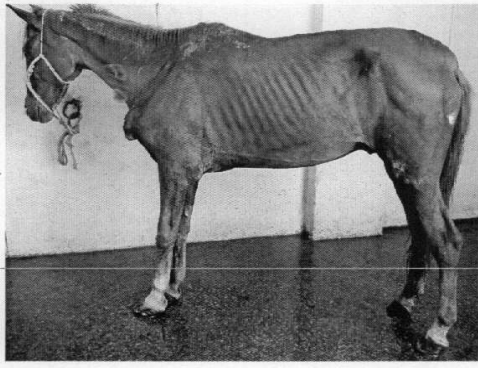


Fig. (1): Showing typical attitude of acute laminitis in 10 years old horse.

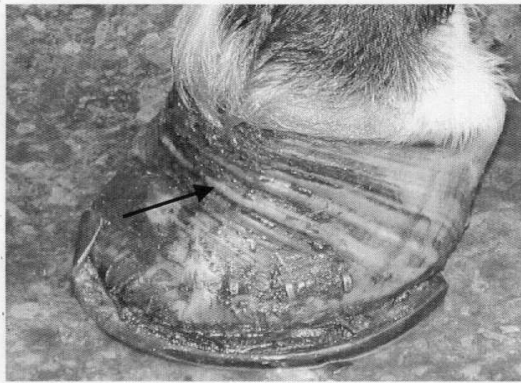

Fig. (2): Showing wide spaces between rings at heel and toe (arrows) in 7 years old horse. (chronic laminitis)

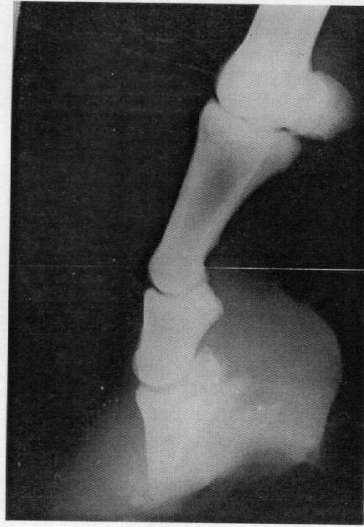


Fig. (3): Lateral plain radiograph revealing rotation of the 3rd phalanx in 11 years old mare.
(chronic laminitis)

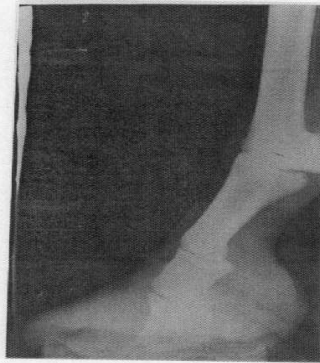

Fig. (4) : Lateral plain radiograph providing rotation of 3rd phalanx in 7 years old donkey.

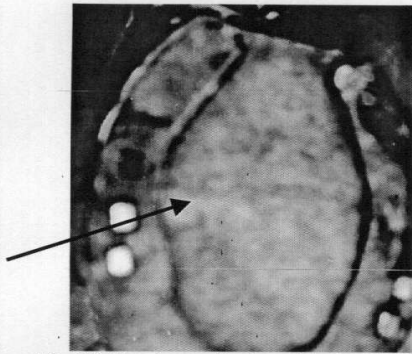


Fig. (5) Showing application of leather shoe in 9 years old horse.

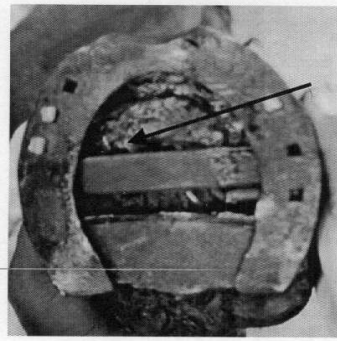


Fig. (6) Showing application of bar shoe in 11 years old mare suffering from chronic laminitis.

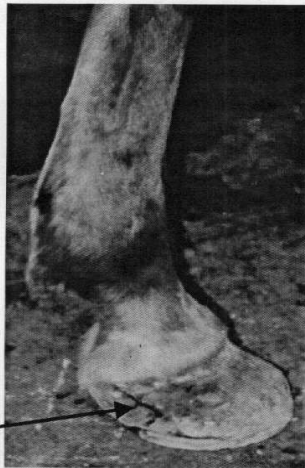

Fig. (7): Showing oblique cracks in the wall originated from the coronet of pelvic limb in 8 years old mule.

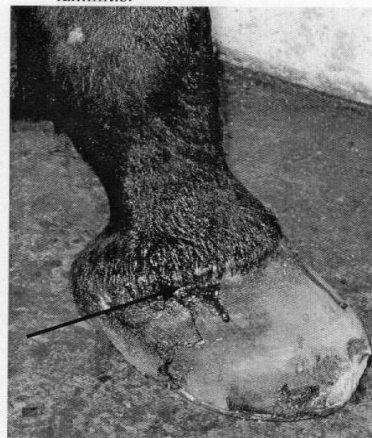

Fig. (8): Showing exudate associated with deep cracks in 10 years old horse. (complicated sand crack)

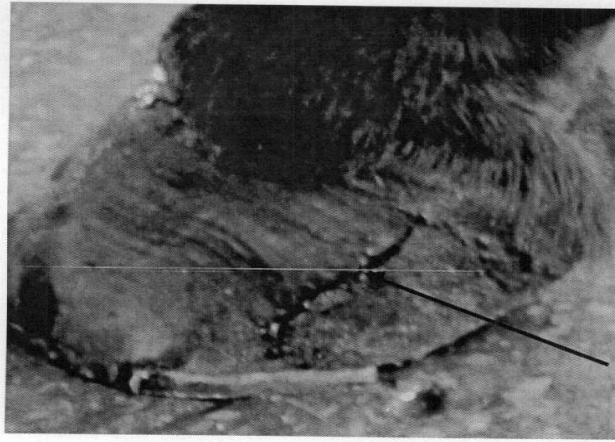


Fig. (9): Showing lateral view of the hoof with longitudinal crack (arrow).

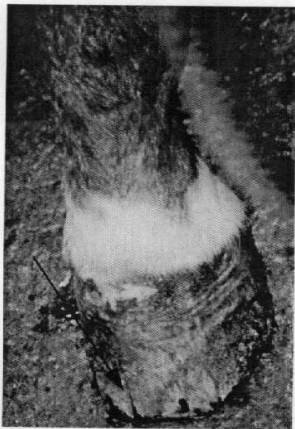

Fig. (10): Showing superficial cracks of 7 years old horse, arising from the bearing surface of the wall.

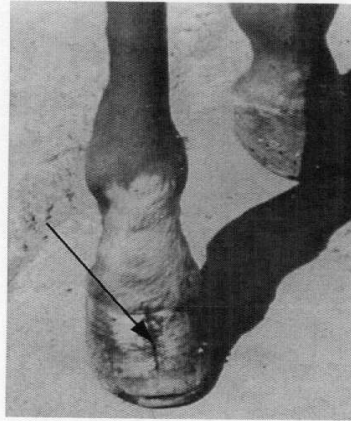


Fig. (11): Showing treated sand crack in 8 years old mule by stainless steel wire.




Fig.(12): Showing a thrush of the hoof characterized by black exudate in 6 years old donkey.

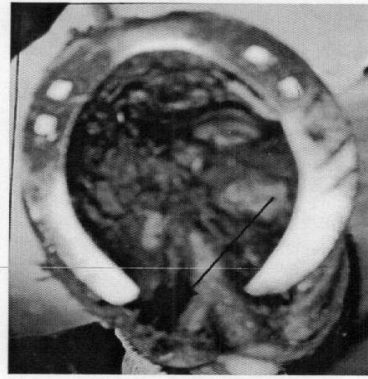


Fig.(13): Showing extension of infection to sensitive structures in 9 years old mare.(thrush)

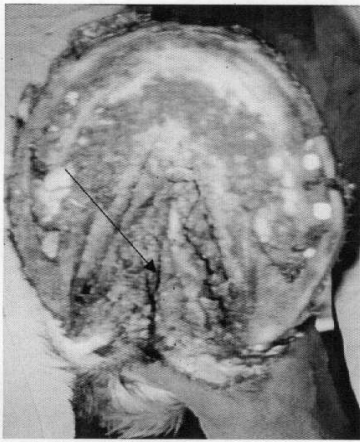

Fig.(14): Showing a thrush after removal of shoe and thinning in 9 years old mare

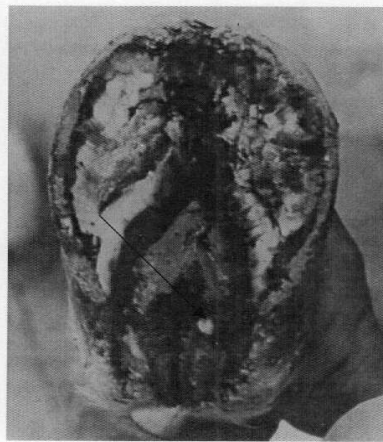


Fig. (15): Showing the solar aspect of 9 years old mare with thrush after recovery.

In this study 139 cases including 90 horses (66 male, 24 female) 33 donkeys (20 male, 13 female) and 16 mule were affected with **seedy toe**. 70 cases were found in the thoracic limb of unshod animals and 67 in the pelvic limb. The wall of the affected hooves was separated from the subcorneal tissue (Fig., 16).

These cases were treated by removal of the abnormal horny materials, application of tincture of iodine, medical tar and local nitrofurazone ointment. All cases cured within a period of 3 months.

In the present study 7 cases of **hypergranulation tissues** were met within 5 horses(3 male, 2 female) and 2 male donkeys .4 cases in pelvic limb and 3 in thoracic limb (Fig.,17).

Treatment in all cases was carried out by total extirpation of the hypergranulation tissue with local dressing with sulphonamide powder after disinfection with betadin and then application of bandage. Complete recovery was obtained after five times of dressing within one month (Fig.,18)

In this study **corn** was present in 46 cases included 25 horses (17 male and 8 female), 17 donkeys (9 male and 8 female) and 4 mules. Corn occurred most frequently on the inner angle of the front feet in 37 cases and were founded in the hind feet in 9 cases.

21 cases affected with suppurative corn became infected resulting in necrosis of the sensitive laminae, (Fig., 19)

The first interference was done by removal of the shoe, removal some of the tissue over the corn without exposing the sensitive tissue. In case of suppurative one exposing the sensitive tissue and soaked in betadine after which tincture iodine was applied. Moist corn responded rapidly to the treatment with tincture iodine and copper sulphate crystal within one week, while the cases of suppurative corns took longer time till complete recovery within 3 weeks.

In this work 4 cases including 3 horses (2 male, 1 female) and 1 male donkey showed **quittor**. Swelling, heat and pain over the coronary band in the region of affected collateral cartilage, and chronic suppurative sinus tracts were seen as in (Fig., 20). The surgical excision of necrotic cartilage just dorsal to the coronary band over the diseased collateral ligament followed by soaking the foot in antiseptic solution. The wound was flushed with a 1 % povidine iodine solution was occurred. The foot and sole were protected by bandage in 2 cases. The other 2 cases were treated by removal of necrotic tissue using 20 % silver nitrate solution followed by saline injection above coronary band in necrotic collateral ligament. The surgical excision was more effective.

In this study 4 horses (3 male, 1 female) were recorded suffering from **canker**. Affected feet were the hind limb in 3 cases and 1 case in the fore limb. All of diseased animals were those stands in mud or in bedding that is mixed with urine and feces and whose feet don't receive regular attention.

In early stages, 3 cases did not show lameness. Examination of the foot revealed a faetid odour and the frog, which may appear intact, has a ragged appearance. 3 cases were diagnosed with loosening of the horny material which removed easily with foul smelling. Swollen corium with chronic vegetative growth were seen (Fig., 21).

Treatment was performed by removal of all loose horn and affected tissue and applying tanic acid dressing. 5 % picric acid was applied under the bandage, mixture of copper sulphate and zinc sulphate crystals were used. Also pencillin with rate 3 million units intramuscularly daily for 10 days. Duration of treatment from 2 weeks to 6 weeks . Also pencillin ointment was applied

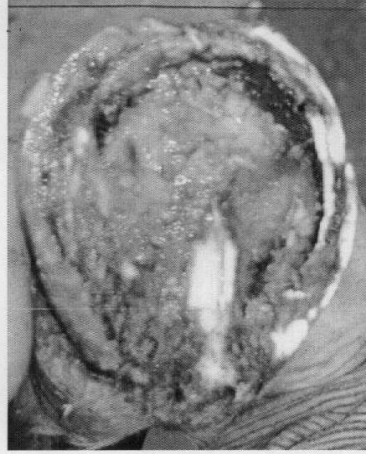

Fig. (16): Showing seedy toe in left pelvic limb in 8 years old horse.

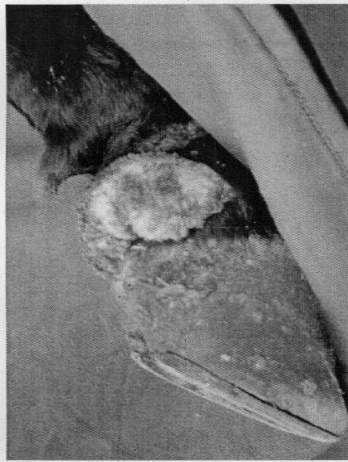


Fig. (17): Showing clear hypergranulation tissue in the lateral aspect of coronary and pastern region in 7 years old mule.

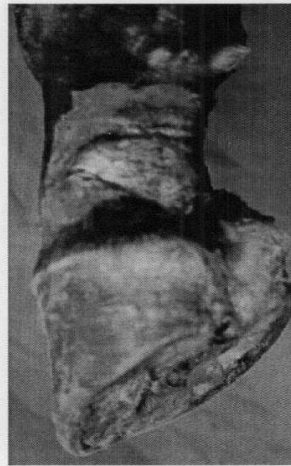

Fig.(18): Showing healed area after excision of hypergranulation tissue in the same previous case.

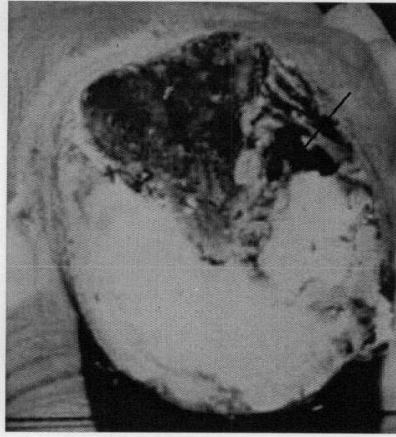


Fig.(19): Showing area of necrosis in the sensitive Laminae indicating suppurative corn in 7 years old

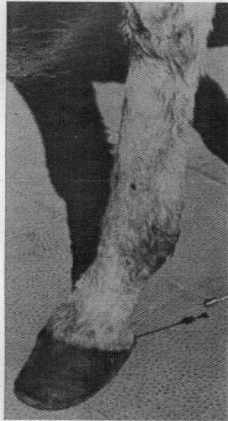

Fig. (20): Showing sinus indicating quittor in 5 years old donkey.

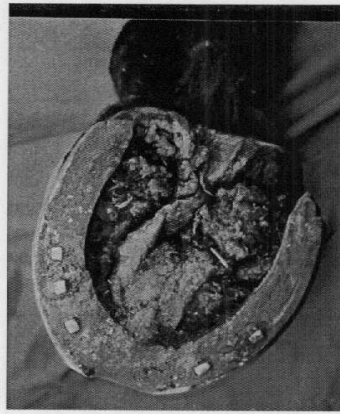


Fig. (21): Showing vegetative growth in the hoof of 9 years old horse.

9 cases showed **inflammation of the coronet (coronitis)**, 6 horses (4 male, 2 female) and, 3 donkeys (2 male, 1 female). In all cases the skin showed excoriation as in (Fig., 22). 2 cases showed purulent exudates as in (Fig., 23). Treatment performed by washing lesion with betadine after removal of horny material, and application of coal tar and cod liver oil with ratio 1 : 6 under pressure bandage. Complete healing was achieved within 2 weeks after dressing.

25 cases included 16 horses (7 male, 9 female) and 9 donkeys (6 male, 3 female) were affected with **elongation of the hoof**. 12 cases were affected with forward and upward elongation of their hooves as in (Fig., 24). Animal bears weight on the heel for long duration that lead to chronic deformed arthritis at the fetlock joint.

9 cases were affected with elongation and outward deviation of their hooves. In this form, the heels were found lowered and 4 cases were affected with recent elongation which lead to abnormal and difficult to walk.

In all cases of deformities with elongations upward and outward deviation were corrected by trimming and rasping until hoof takes its normal shape.

In the present study, 88 cases of **penetrating wound** included 54 horse (33 male, 21 female), 28 donkeys (17 male, 11 female) and 6 mules were met with 56 cases were punctured wound in the middle third of frog and 32 cases in the sole. In 15 cases, infection was occurred. In 43 cases puncture in the heel of the sole, animal attempted to land on the toe. 45 cases were characterized by presence of wound in the toe region of the sole, animal land on the heel. cases of wound in the lateral side of the sole, animal attempted to carry most of weight on the medial aspect of the foot. The site of nail characterized by black spots in the sole. These black spots were probed until their full depth was determined as in (Fig., 25).

10 cases of punctured wounds of the hind foot caused a stringhalt attitude to the gait. The animal moves the limb in a hyperflexed manner due to damage by nail that reached the 3rd phalanx.

Animals were given antitetanic serum and streptopencid administration. The foot was daily soaked in Magnesium sulphate solution, flushing with 1 % povidone iodine solution in the tract for 3-4 days after that foot was bandaged. Satisfactory results were obtained 3 weeks after interference, especially those located in the sole.

Only 2 cases of male horse were diagnosed by radiographically as **side bone** one was recognized complete bilateral (Fig., 26) and the other partially bilateral (Fig., 27). Treatment was made by incision of fragmented portion of the bone. Local application of penicillin ointment bandage was applied.

In this study 2 cases of **pedal osteitis** in 2 male horses were recorded.. Lameness was obvious in all gaits. Examination by hoof tester revealed pain at the bottom of the foot. Radiographs indicated demineralization at one or more points in the distal phalanx as shown in (Fig., 28) and (Fig., 29).

Treatment of these 2 cases was performed by resting the animal , shoeing for keeping the sole away from the ground using leather shoe and topical application of equal parts of phenol, formaline and iodine. Intravenous injection of Finadin for 5 days was also done. The 2 cases did not respond to this treatment.

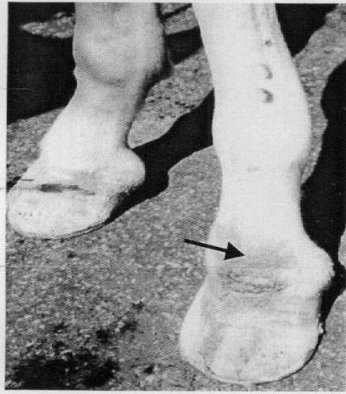

Fig.(22): Showing inflamed (local) skin in the coronary region in 7 years old donkey.(coronitis)

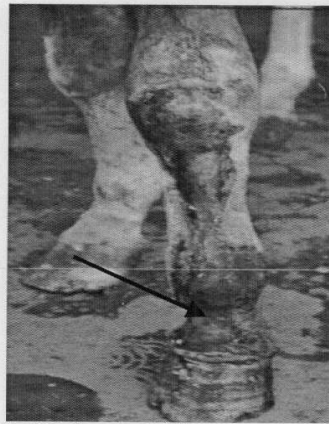


Fig.(23):Showing inflammation of coronet in 8 years old donkey.




Fig. (24):Showing elongation of hoof with sand crack in 7 years old donkey.

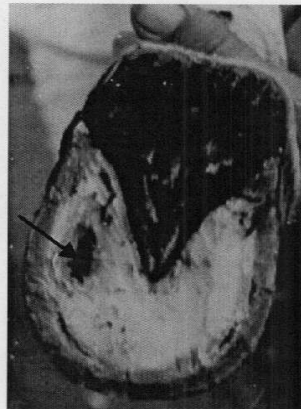


Fig. (25): Showing punctured wound in the sensitive structure of the sole in 5 years old donkey

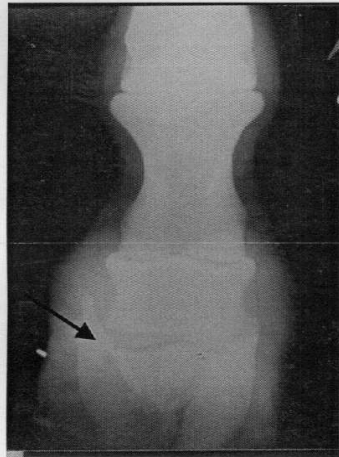


Fig. (26): Showing radiograph of bilateral side bone in 9 years old horse. (Partial)

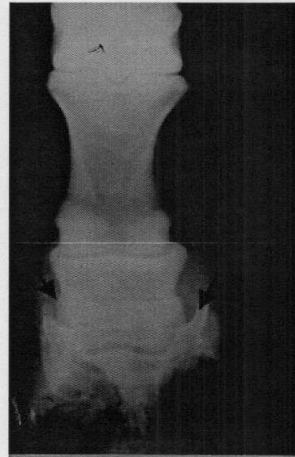

Fig. (27): Showing radiograph of bilateral side bone in 8 years old horse.

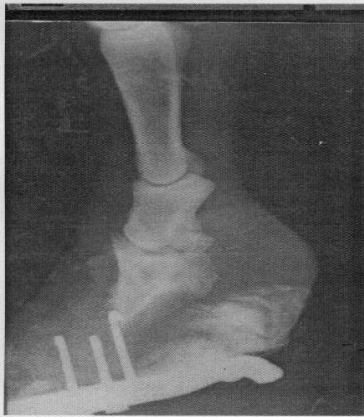

Fig. (28): Showing roughening in the distal

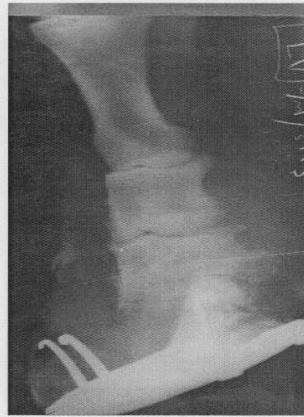

Fig. (29): Showing roughening in the distal

phalanx (pedal osteitis) 5 years old horse.

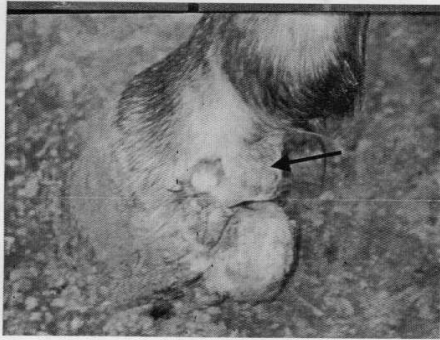


Fig.(30): Showing localized circular swelling in the caudal aspect of coronet in 7 years old donkey.

phalanx (pedal osteitis) in 6 years old horse.

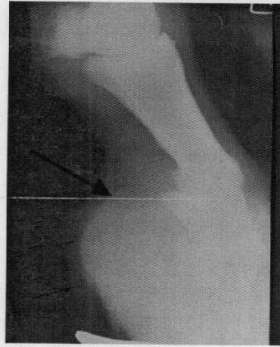


Fig.(31): Showing radiograph providing an increased soft tissue density at the coronet (arrow).

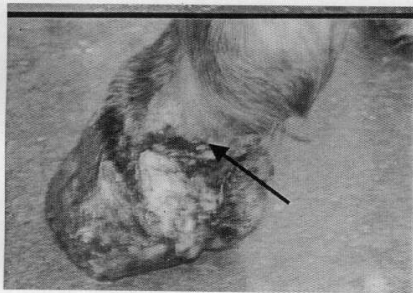


Fig. (32): The same previous case after surgical excision of the tumour.




Fig.(33): Showing knuckling over with injury of the coronet lateral view in 7 years old donkey

Tumour at the hoof along this study appeared in 4 cases including 3 horses (1 male, 2 female), and 1 donkey. It was characterized by abnormal growth at the coronet. Lameness appeared as a result of pressure of growing tumour on the sensitive tissue as in (Fig.,30) by radiographs there was increase in tissue density at coronary region (F.,31). The treatment depended on surgical removal of abnormal growth. Bandage was applied with gentamycin spray. Dressing with antibiotic and bandage were repeated every 3 days until recovery was obtained (Fig., 32).

In the present study 5 cases showing **knuckling over** were met within 3 horses (1 male, 2 female) and 2 donkeys. Affected animals were bearing weight on the dorsal aspect of the hooves of the pelvic limbs with injuries of the skin above the coronet. (Fig.,33) and (Fig.,34). Pairing was done to the hoof with application elongated shoe as in (Fig., 35)..

5 cases including 4 horses (3 male, 1 female), 1 male donkey, were recorded suffering from **navicular disease**. History of the affected animal denotes intermittent lameness that decreases when it was during rest. By using hoof tester to check the medial and lateral sides of the central third of the frog or test the end of the navicular bone.

The treatment was achieved by curetting the sole with a hoof knife. All cases were corrected by palmer digital neurectomy of the medial and lateral palmer digital nerve under the effect of procaine HCl 3 % as nerve block anesthesia preceded by combelen as preanaesthetic agent.

Only 1 case of racing horses 1 male was recorded suffering from **fracture of the distal phalanx**. Lameness occurred suddenly during work and no trauma had occurred. There was increased digital pulsation and heat in the affected foot. Examination with hoof tester and percussion revealed pain over the entire sole Region.

X ray film showed complete longitudinal fracture as in (Fig.,36) Trials for treatment were done by using a full bar shoe with quarter clips. The bar was placed on the shoe. The case did not respond to this treatment.

were done by using a full bar shoe with quarter clips. The bar was placed on the shoe. The case did not respond to this treatment.

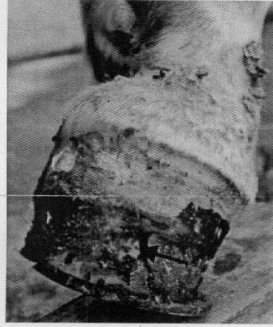


Fig. (34): Showing caudal view of the same previous case. Knuckling at the toe with crack.

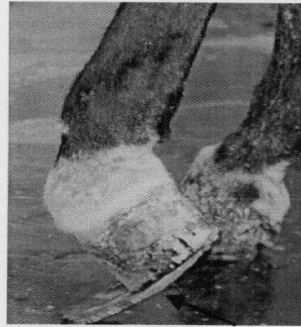


Fig. (35): Showing paring the hoof with elongated shoe for treatment of knuckling at the toe in 5 years old donkey

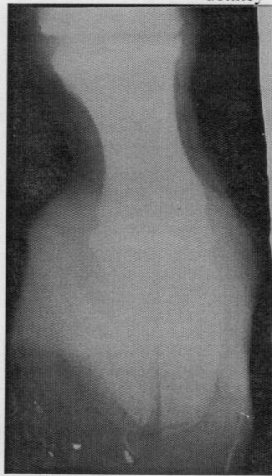


Fig.(36):Showing dorso-palmer plain radiograph providing complete longitudinal fracture of 3rd phalanx in 6 years old horse.

Discussion

This study gives an attention to prevalent hoof disorders in equine especially horses which is considered the most important and economical domestic animal industry all over the world and Egypt.

The main causes of hoof disorder is improper trimming and shoeing , soiled ground under the animal especially had urine and feaces. This agrees with opinion of El-sheik (1992) who said that hoof affections in equine were mainly due to improper trimming and shoeing. Malconformation of the feet, unbalanced ration, hereditary factors, complication of puncture wounds of the sole, corns and post parturant infection. May also play an important role for producing hoof disorders.

Acute laminitis was met with during the present investigation due to dietetic error. The animal was standing with the fore feet in front of the body, and hind feet under the abdomen. All feet were affected. The local symptoms were those of acute inflammation, heat and pain. The cause was over feeding of these animals with larger amount of grains. This is in agreement with the findings of Annon (1966), Coffman and Garner (1972), , and Annon (1966) added to the above mentioned causes that, drinking large amounts of cold water is one of the main causes of laminitis. While Garner, Coffman, Hahn, Ackerman and Johnson (1975) added that, age sex, season and breed are risk factors associated with equine laminitis.

In chronic from of laminitis, rings on the hoof wall were seen close at the toe and widely separated at the quarters and heels. Similar results were obtained by Frank(1961) , Colles and Jeffcot (1977) and Saleh (1982).

Decreased blood flow to the laminar corium of the hoof during acute laminitis, resulted in disturbances in the processes of keratinization within the hoof. Poor blood flow associated

with poor keratin production and body weight of the animal leads to disconfiguration in the shape of the hoof (Colles and Jeffcot (1977) and Barakate, 1989).

The first aid of treatment of acute laminitis was application of ice packs. The diseased animal was prevented to feed on grains but hay was allowed. Mineral oil and Antihistaminic (Avil) were given to the diseased animal. Injection of 2 ml Carbacol subcutaneously proved to be the suitable treatment for acute laminitis (O'connor 19, Annon 1966, Coffman and Garner 1972 and Adams 1987). While Moore (1915) and Rodebaugh (1938) advised surgical treatment of acute laminitis activated by free blood letting. In addition, Chavance (1946) and Annon (1966) advised injection of Antergan solution in treating post parturant laminitis which give complete recovery after 5 days, Injection of Neo-antergan in treating alimentary laminitis gave complete recovery within 48 hours. Annon (1966) advised using 20 cc mepyramine maleate and obtained complete cure within 10 days.

The chronic cases of laminitis were corrected by rasping the hoof and application of a leather shoe to prevent perforation of the sole. This method was proved to be the suitable treatment of chronic laminitis by (White and Boggett, 1983). While Jenny, et al. (1965) advised using acrylic hoof repair material. In addition, Coffman, Johnson, and Fishburn (1969) used adrenocorticotrophic hormone therapy with Vit. B-complex.

Complete superficial sand crack was met with in this study. Toe crack was commonly observed more than quarter crack. It was found that, sand crack, usually affected the quarter of the wall in thoracic limb and the toe of the pelvic limbs Occurrence of cracks attributed to unequal distribution of weight on foot as well as alternative moisture and dryness of the horn and excessive growth of the hoof. Similar results were obtained by Frank (1964), O'connor (1965), Evan, et al (1966), El-Guindy (1981) and Bolbol and Saleh (1987).

Referring to the treatment of sand crack paring the fissure from both edges was performed to diminish pressure on the sensitive tissue; the gap was filled with medical tar. The coronary region was blistered by mercuric iodide, and pressure bandage with a special shoe

were applied. This technique proved to be the satisfactory treatment of sand crack by (O'connor, 1965 and Hickman, 1981). While Jenny et al (1965) advised umbilical tap lacing in order to provide a better mechanical support for filling material. While, Evans, et al (1966) reported filling the hoof crack with adhesive acrylic. In addition, Adams (1987) stated that, plastics epoxy glues fiber glass or special hoof materials can be used.

In the present study thrush was more prevalent in the pelvic limb than thoracic limb. It was found that donkeys were affected more than horses. In all cases, there were exudation which varies from slight dark colour to black colour accompanied with foeted odour arised from central and lateral sulci. It was revealed that prolonged standing of the affected animal in muddy ground and bedding mixed with urine and feces was the main cause of thrush Similar results were obtained by (O'connor, 1965, Fessler, 1971, El-Guindy, 1981, Saleh, 1982, Adams, 1987 and Bolbol, and Saleh 1987).

Surgical manipulation of the cases affected with thrush was done by removal of all desentigrated horny material, paring and cleaning the central and lateral lacunae. Then washing the sole with copper sulphate solution 5 % after that formaline was used as drying agent. Finally application of kopertox topically Proved to be a good treatment for thrush. The same treatment was reported by (Fessler, 1971, Johnson, 1972, and Adams, 1987). While, Adams (1987) advised using sodium sulfapyridine solution 10 % topically

Concerning seedy toe, this affection was found to affect thoracic limb of unshoed animals. The wall of the affected hooves were seen separated from the subcorneal tissue after removal of the abnormal horny materials. The affected animals revealed moderate degree of lameness. Similar findings were obtained by (O'connor, 1965, Shuttelworth, 1966, Awad, 1967, El-Guindy et al., 1986 and Bolbol and Saleh 1987). One case was associated with hoof cracks beginning from the ground surface but not exceed more than half the length of the wall. It comes in agreement with (Saleh, 1982).

Surgical removal of the disintegrated parts, packing the cavity with tar, application of blister at the coronet with application of a leather shoe proved to be successful treatment of seedy toe in equine (Jenny et al., 1965).

In this study, corns were found to be located more frequently at the medial angle of the hooves. Purulent corn was the most common but moist corn was met within one case only. All corns were found in the left thoracic limb. It was found that, the increase of the percentage of suppurative form due to carelessness of the owners leaving the case till suppuration were obtained O'Connor (1965), and Adams (1974).

The first aid of the treatment in all cases was removal of the shoe, paring and thinning the horny layer of sole around the lesion and giving antitetanic serum. In case of moist corn dressing by tincture of iodine with copper sulphate baths and hoof bandage was beneficial. While the purulent corn was treated by immersing the affected hoof in 10 % formaline after removal of the pus and necrotic tissue. This agrees with the opinion of O'Connor (1965).

In this study quittor showed swelling, heat and pain over the coronary band in the region of affected collateral cartilage. Chronic suppurative sinus tract were seen. These results come in agreement with opinion of O'Connor (1965) who mentioned that the disease is a chronic purulent inflammation of the collateral cartilage of the third phalanx characterized by necrosis of the cartilage and sinus drainage through the coronary band.

Referring to canker was found mostly in hind limb than fore one. These animals stand in mud or bedding soaked with urine. Lesion characterized by loosing of the horny material which moves easily with foul smelling, swollen corium with chronic vegetative growth. This agreed with Mccum (1974) who mentioned that bad hygienic conditions in animal enclosures especially the presence of muddy stand containing bedding saturated with feaces and urine. Improper care of the feet as well as atrophy of the frog seemed to favor the onset of canker. This also agrees with that opinion of O'Connor (1958), and Johnson (1982)

who mentioned that the affection is more seen in the hind feet. It may involve one or all feet. Lameness evidenced in advanced cases together with the characteristic foetid odour and the chronic vegetative growths (Ergots) of the sensitive tissue are diagnostic.

In the present study coronitis was found at the pastern region in donkeys. The wound was characterized by skin excoriations, loss of hair and somewhat moderate degree of lameness. This affection was present at the planter surface of the pastern in the pelvic limb. These results are in agreement with the opinion of O'connor (1965) who mentioned that the disease most commonly affect ass and mule chiefly at the toe and quarters, due to irritation by dry mud on the coronet or prolonged moisture .

Coronitis may develop as a result of the bad habits of some owners who used to a hard rope or wire around the coronet to restrict the movement of the animal (to keep the animal stand still.)

Surgical manipulation of the inflammation of the coronet was carried out by washing the lesion by 10 % povidone iodine and coal tar under bandage. This proved to be a good method of treatment (O'Connor, 1965).

Concerning hoof elongation of both limbs of equine were recorded. The recorded cases were characterized by upward elongation of the hooves which lead to bearing weight on the heels and upright pastern, elongation and outward deviation of the hoof, and slight elongation of the hooves without complications. Beside outward deviation of the hoof which was mainly observed in donkeys affecting both pelvic limbs leading to luxation of pastern joint. This is in accordance with the findings of (Annon, 1966 and Soliman,1989).

It had been found that hoof deformities in equine could be attributed to persistent standing of those animals in a confined housing without any work or even mild exercise, beside neglected trimming of their hooves for several years. All these findings were similar to the results of Lambert (1966), Emmery et al.(1977), Ahmed(1979).

The present results also proved that not all patterns of hoof deformities are accompanied with complications. This fact could be supported by the recent elongated hoof, deformity that requires regular trimming of the excessive horny material. This result coincide with those reported by Soliman (1989). Hoof should be cleaned and trimmed regularly every 4-6 weeks advised by Annon, (1966) and Adams (1987).

The most important and serious affection met with in the present study was punctured wounds of the sole. Horses were more frequently affected than donkeys. Thoracic limbs were affected more than pelvic limbs. Punctured wounds of the sole were found at the apex of the frog, due to penetration of nail or sharp-pointed objectes. Similar observations were seen by O'connor (1965), Johnson (1970) and Adams (1987) who mentioned that, sole could be punctured at any part, at the toe, quarters, apex of the frog, central and lateral lacuna and heel but the bar is seldom penetrated. Meanwhile Johnson (1972) mentioned that, submural abscess result from punctured wounds in white line. In addition Adams (1987) reported that, punctured wounds in the middle third of the frog causes puncture of navicular bursa while punctured wound of the sole cause fracture and necrosis of os pedis.

The important point for surgical interference in treating punctured wound of the sole was applying free drainage. This was activated by paring and thinning of the horny layer around the punctured wound. Application of phenol and formaline 3-4days with the help of sulphonamide powder until the wound completely dried, then a leather shoe is applied, as well as antitetanic serum. This handling proved to be the excellent method for treating punctured wounds of the sole. This is in agreement with that of Burrows (1938), O'connor (1965), Jhonson (1970), Johnson (1972) and Adams (1987). while, Jenny, et al. (1965) recommended dressing the punctured wounds at the sole with plastic hoof repair material (soft acrylic).

In this study side bone was diagnosed by X-ray it was characterized by ossification of collateral cartilage which may be partially or completely ossified . This agrees with Johnson (1982) and Lunduall. (1965) who defined sidebone as an ossification of the collateral cartilages. And with opinion of Adams (1987) who described that; radiography will reveal that the cartilages have partially or completely ossified.

As regards pedal osteitis, was diagnosed by X-Ray, which was characterized by demineralization of the distal phalanx at one or more points with roughening in the distal phalanx .This agrees with Lunduall, (1960) who defined pedal osteitis as demineralization of the distal phalanx resulting from inflammation. It usually manifests itself radiographically as roughening of the solar borders of the distal phalanx. Although the problem may be found anywhere in the distal phalanx, it is usually confined to the toe and wing regions of the front feet.

In this study tumour was found as abnormal growth at the coronet and appeared as a result of pressure of growing tissues on the sensitive tissue. By radiograph, there was an increase in tissue density.

During this investigation, knuckling over of the second degree was seen in a donkey. Affected animal bears weight on the dorsal aspect of the hooves of the pelvic limbs with injuries to the skin above the coronet. These results coincide with that discussed by O'connor (1965) who reported that, excessive volar flexion of the phalangeal Joints may be due to cicatricial contraction of the tendon following chronic tendonitis or secondary to other lesions as ring bone and diffuse osteoperiostitis of the pastern. Tenotomy of deep flexor tendon has been done but without satisfactory results due to ankylosis of the pastern joint.

Our results indicated that, one of the most dangerous disease affecting the hoof of the horse was navicular disease. The animal was pointing his thoracic limb alternately when at rest, while during movement he tends to land his limbs on the toe of the hoof. Both thoracic limbs were affected. These results are in agreement with that mentioned by O'connor (1965), Ackerman, et al (1977) and Adams (1987) who recorded that, navicular disease affects fore limb in horses between 4-15 years of age.

Diagnosis of navicular disease was based on history intermittent lameness that decreases during rest a fact which agrees with El-baroudy (2005) who reported that the inspection of show jumper horse walking or trotting through lameness evaluation, with short limb stride, tended to land on the toe and May occasionally stumbled, however our attention were focused toward navicular disease.

Bilateral palmar digital neurectomis combined with corrective shoeing are of some help in treating navicular disease. This is, in agreement with O'Connor (1965) and Ackerman et al (1977). While Jories (1986) advised injection of phenylbutazone with the corrective shoeing by which raising the heel in early acute phase. In addition, Adams (1987) described intrabursal injection with irritants such as lugol's iodine. He also described peripheral vasodilating agent such as isoxsuprine hydrochloride as medical treatment.

In this study one racing horse was met with affected with fracture in the distal phalanx and lameness occurred suddenly .a fact which is in agreement with Scott et al (1979), Weaver (1969) and Yovich, et al (1982). who reported that fractures of the distal phalanx are not common. It is usually associated with exercise on hard tracks, and the fore feet, particularly the left fore foot, appears to predispose in horse racing counter clockwise.

Summary

A total of 823 animals of the equines were inspected to point out the prevalent affections of the hoof. Number of the examined animals which had hoof disorders included 497 horses (60.4%), 242 donkeys (29.4 %) mules (10.2%).

These animals were collected from, Army sport clubs in Cairo and Alexandria, Principle Veterinary hospital, Brook hospital for animal and Vet. clinic at Faculty of Vet. Med. Alex. University.

The obtained results could be summarized as the following. Horses represent 497 heads of total affected number of equine, 49 cases of acute laminitis,64 cases chronic laminitis ,84cases with sand crack, 82 cases with thrush 90 cases seedy toe, 5 cases with hyprgranulation tissue,25 cases with corn,3 cases with quitter,4 cases with canker,6 cases with inflammation of coronet,16 cases with elongation of the hoof, 54 cases with puncture wound of the sole,2cases with side bone, 2 cases with pedal osteitis, 3 cases with tumour of the hoof,3 cases with knuckling over, 4 cases with navicular disease and only one case with fracture of the phalanx.

In this study donkeys represent 242 heads of total affected number of equine, 29 cases of acute laminitis,37 cases chronic laminitis,46 cases with sand crack, 33 cases with thrush, 33 cases seedy toe,2 cases with hyprgranulation tissue, 17 cases with corn,1 cases with quitter,3 cases with inflammation of coronet, 9 cases with elongation of the hoof, 28 cases with puncture wound of the sole, 1 cases with tumour of the hoof,2 cases with knuckling at toe,1 cases with navicular disease.

In this study mules represent 84 heads of total affected number of equine, 12 cases of acute laminitis,16 cases chronic laminitis,17cases with sand crack, 13' cases with thrush 16 cases seedy toe, ,4 cases with corn, 6 cases with puncture wound of the sole.

Types and location of the affections of hoof in equine were recorded. The examined animals aged between 2-15 years old.

The surgical interventions in most cases were performed under the different types of anesthesia and tranquilizers as Rompun, Combelen, Procaine adrenaline and Chloral hydrate.

The prevalent affections among equine were, 90 cases of acute laminitis (10.9%), 117 cases chronic laminitis(14.2%),147cases with sand crack(17.8), 128 case with thrush(15.5%), 139 case seedy toe(16.8%) ,7 cases with hypergranulation tissue(0.9%),46 cases with corn(5.6%),4 cases with quittor(0.5%),4 cases with canker(0.5%),9 cases with inflammation of coronet(1.1%),25 cases with elongation of the hoof(3%), 88 cases with puncture wound of the sole(10.7%),2cases with side bone(0.2%), 2 cases with pedal osteitis(0.2%),4 cases with tumour of the hoof(0.5%),5 cases with knuckling over(0.6%) ,5 cases with navicular disease (0.6%),only one case with fracture of the phalanx(0.1%),

Hoof affections in equine were found to be mainly due to improper trimming and shoeing, malformation of the feet unbalanced ration, hereditary factors, complications of punctured wound of the sole, corns and post parturient infection.

It is found that locality and nature of housing considered as important factors in causing hoof affections. For example thrush, seedy toe, and coronitis were common in the presence of muddy and moisture, while sand crack was present in dryness and moisture Seedy toe was usually observed also in unshod animals.

There are especially two reasons why hoof care is important:

1. Draught animals are kept under man-made environments, often in confined quarters and quite wet conditions.
2. Additionally, they are used for work that makes higher demands on their hoofs than would have been the case if they had just moved around normally as they would when grazing. The limited accommodation and wet conditions counteract the normal wear and tear of the hoof and an animal kept under kraal or stable conditions without it receiving the correct hoof care, tends to develop hoof rot.

REFERENCES

- Ackerman, N., Garner, H. E., Coffin, J. R., and Clement J., (1975) Angiographic appearance of normal equine foot and alteration in chronic laminitis. J. A. V. M. A. 166 (1), 58 – 62.
- Ackerman N., Johnson J. H., and Dorn C. R., (1977) Navicular disease in the horse, Risk factors radiographic changes and response to the therapy J. A. V. M. A. Vol. 170 No. (2) 183-187.
- Adam's O. R., (1974) lameness in horses, 3rd Ed. Lea and Febiger, Philadelphia, U.S.A.
- Adams' O. R., (1987) Lameness in horses 4th Ed. Lea and Febiger, Philadelphia, U.S.A.
- Ahmed A. S., (1979) contribution to hoof deformities and its pathological changes in donkeys. Khaled ben elwalid press , Damascus , Syria
- Allen D. J. R., Foerner J. F., Gordon B. J.,(1986) Surgical management of chronic laminitis in horses: 13 cases J Am Vet Med Assoc. 1986 Dec. 15;189(12):p 1604-1606
- Annon N., (1966) Lamenesses of the foot, Med. Vet. Prac, Red, Book 47 – No.5 (84 – 93)
- Awad M. A. T., (1967) Surgical affections causing lameness in equines M.V. Sc. Thesis, Faculty of Vet. Med. Zagazig Univ.
- Baird J., (1933) Lameness and its treatment in the horse. J. A. V. M. A., 83(1):39-49

- Barakate M., (1989) Contribution to some prevalent hoof affections in horses (clinical review) Alex. J. Vet Sci. 6 No. (1) 693-700.
- Barakat Christine (2000) Spot the Hoof Disease Laminitis Early, May 2000 EQUUS magazine.
- Bolbol A .E., and Saleh. A. S., (1987) Survey on equine hoof affections in upper Egypt, J. Egypt Vet. Med. ASS 47, No. 1 & 2, 545-553.
- Breningstall T.(1997) Treating Sand Cracks, Equine Veterinary Education 9, no. 3: 143-154
- Burrwos S., (1938) Disease of the foot of the horse, Vet. Med. P (216- 225)
- Charlotte L., (2002) Oklahoma State University College of Veterinary Medicine
VMED 7123 Veterinary histology
- Chavance, J., (1946) Histamine theory and treatment of laminitis. Vet. Med. Vol. 41 p(199-202).
- Coffman, J. R., Johnson J. H., and Fishburn, F. J., (1969) Management of chronic laminitis in the horse. J. A. V. M. A. Vol. 155 No.(1) p(45-49)
- Coffman , J. R. and Garner H. E., (1972) Acute laminitis, J. A. V. M. Vol. (161) No. 11 p (1280- 1283)
- Colles C. M., and Jeffcott L. B., (1977) Laminitis in the horse, Vet . Rec. 100, (262-
- Dellman H. D.,(1981) Textbook of Veterinary Histology." 4th Ed, Lea & Febiger,
- Denoix J. M., Thibaud D., Riccio B., (2003) Tiludronate as a new therapeutic agent in the treatment of navicular disease: a double-blind placebo-controlled clinical trial, Equine Vet. J. Jun;35(4):407-13.

- Diverst. J.(2003) Prevention and treatment of thrombosis, phlebitis, and laminitis in horses with gastrointestinal diseases. Vet. Clin. North Am. Equine Pract. 2003 Dec;19(3):779-90.
- Dorn,(1975) Castration and other factors affecting the risk of equine laminitis, Cornell Vet., 65:57
- Dubs B., and Nemeth F., (1972) Therapy and prognosis of pedal bone Fracture schweiz. Arch Tierheilkd., 114:423
- Duncan D. B., and Dingwall, J. S., (1971) Surgical removal of avulsed portions of the extensor process of the third phalanx in the horse, J. Am. Vet. Med. Assoc., 159:201
- El-baroudy, (2005) Radiological and surgical studies on prevalent disorders of the limbs in sport horses, M. V. Sc. (Vet surgery), Alex University.
- El-guindy, M. H., (1981) Regional and operative surgery . 2nd Ed. Khaled ben elwalid press , Damascus , Syria
- Eliashar E., Meguigan M. P., Wilson A. M., (2004) Relationship of foot conformation and force applied to the navicular bone of sound horses at the trot. Equine Vet. J.Jul;36(5):431-5.
- Ekfalk A., Rodriguez H., Obel N., (1992) Histopathology in post-surgical laminitis with a peracute course in a horse, Equine Vet. J. 1992 Jul; 24(4):321-4 No.PMID:1499543
- Emmery L., Miler J., and Van Hossen N. V., (1977) Horse shoeing theory and hoof care 4th Ed. Philadelphia, Lea. And febigen. U.S.A.

- El-sheikh, (1992) Prevalent affections of the pes and manus in equine and cattle in behira province, M. V. Sc. (Vet surgery), Alex University.
- Eustace R.A. (1992a) Explaining Laminitis and its Prevention R.A. Equine Vet. J. (1992) 31.spp 433-442
- Evans H., Jenny J., and Raker C. W., (1966) The repair of hoof crack with acrylic . J . A V. M . A. 148 No (4) (355 - 359)
- Fessler J. F., (1971) Sursurgical management of equine foot problems. Med . Vet. Prac. Vol 52 no 3 p (44- 49)
- Febble L., (1973) Supportive ostemyelitis of the pedal bone in a thoroughbred horse, Milit. Med., 138:220
- Frank E. R., (1961) Veterinary surgery , 6th Ed. Burgess publishing company , minneoplis , U.S.A.
- Frank E. R., (1964) Veterinary surgery , 7th Ed. Burgess , publishing company , minneoplis U. S.A.
- Garner, H. E., Coffman, J. R., Hahn, A. w., Ackerman, N., and Johnson J. V., (1975) Equine laminitis and associated hypertension a review. J. A. V. M. A. Vol.(166) No.1 p(56-57).
- Gibbons W. J., (1966) Diagnosis of equine lameness. Med. Vet. Pract.,47,9;62
- Hallet, (1936) Laminitis in horses. Vet. Med. 31:338-340

- Harle R. P., (1985) Management of pastern and heel laceration in horse . Med . Vet. Prac. 66 NO. (5) b (5 - 8)
- Haynes P. F., and Adams O. R., (1974) Internal fixation of fractured extensor process of third phalanx in a horse, J. Am. Vet. Med. Assoc.,164:61
- Hickman J., (1964) Veterinary orthopedics. Edinburgh, Oliver 1st Ed. P (163- 167)
- Hickman, J., (1981) Operation for sand crack. An atlas of vet . med. 2nd Ed. P (154- 155)
- Hood D. M., David M., Connie K. Swenson, and A. Bruce Johnson (1981) Heparin as a preventative for laminitis, J. Am. Vet. Med. Assoc.
- Hood, and Stephens,(1981) Physiopathology of equine laminitis, Cont. Ed., 3:454
- Hood D. M., Johnson, (1982) Equine laminitis past present and future Am. Vet. MED. Assoc. Vol. 132 No.14 p(1210)
- Huntetal, (1994) Vitro evidence for a bacterial pathogenesis of equine laminitis. Veterinary Microbiology 79: 209-223
- Jacobson J. D. and Denbow D. M., (1978) Equine Laminitis -- Another Hypothesis for. Pathogenesis. Medical Hypothesis 30: 203-210
- Jenny J., Evanse L. H., and Raker C. W., (1965) Hoof repair with plasties. J. A. V. M. A. Vol. 147 , No 12 p (1340- 1345)
- Johnson J. H., (1970) Puncture wounds of the foot, Vet. Med / plastics. J. Am. Vet. Med. Assoc., 147(12):1340
- Johnson J. H., (1972) Septic condition pf the equine foot. J. A. V. M. A. Vol. 11 p(1267-1279)

- Johnson J. H., (1982) Equine medicine and surgery 3rd Ed. American Veterinary Publication p(1033)
- Jones G. W., (1986) Equine Lameness, 2nd Ed. Black well scientific 1st Published Bolter and Tanner 1st ed., London.
- Kuwano A., Katayama Y., Kasashima Y., Okada K., Reilly J. D., (2002) A gross and histopathological study of an ectopic white line development in equine laminitis, J. Vet. Med Sci. 2002 Oct;64(10):893-900
- Lambert, F., (1966) The role of moisture on the physiology of the hoof of the horse. Vet. Med. / S. A. C. 61(362-347)
- Lundvall R. L., (1965) Surgical removal of fractured sidebones Proc. 11th Ann. AAEP.
- Lundvall R. L., (1969) Pedal osteitis in horses, Nor Den News 44:16
- Mason J. H., (1962) Penicillin treatment of foot canker, J. S. Afr. Vet. Med. Assoc. 23:223
- Mc Diarmid A. M., and Duff A., (1996) A method of applying frog support in the treatment of laminitis. Equine Vet. Educ., 8, 165.
- McCum J., (1974) Lameness in the horse with special reference to surgical shoeing. Vet. Rec., 63;629-634.
- McClure, (1993) Functional Anatomy of the Horse Foot, University of Missouri-Columbia, A. M. J. Vet. Med. Assoc. 59:180
- Miller J., Les, and Nyles Van Hoosen (1999) Hoof Structure: Lea & Febiger.

- Miller J.,(2000) 'The Darkling Thrush' and the Habit of Singing." Essays in Criticism 36, 2 (April 1986): 121-41.
- Moore, R. C., (1915) Laminitis of the foot. Med. Vet. Prac. P 89
- Moore, R. C., (1979) Intracecal endotoxin and lactate during the onset of equine laminitis , A. M. J. Vet. Res., 401:722
- Moyer W., (1980) Corrective shoeing, Vet. Clin. North Am.[Large Anim. Proct.],2:3
- Obel N., (1948) Studies on the histopathology of acute Laminitis J. V. M. A. B. Z. B. 35,5 p(321-330)
- O'Connor J. J., (1958) Dollar, veterinary surgery.3rd Ed. Bailliere, Tindall and cox, London.
- O'Connor J. J., (1965) Dollar, Vet. surgery.4th Ed. Bailliere, Tindall and cox., London.
- O'Grady S. E., (2001) Quarter crack repair. Am. Farriers J. 1997;17(7):26-31.
- Pettersson H., (1972) Conservative and surgical treatment of fractures of the third phalanx, prac. 18th Ann. AAEP.
- Plakhotin M. V., (1966) General Vet. Sur. 1st Ed. Mir. Publishers Moscow.
- Pollitt C. C., (1995) Color Atlas of the Horse's Foot, Mosby-Wolfe, London.
- Pollitt C. C., and Daradka M.,(1998) Equine basement membrane pathology: loss of type IV collagen, type VII collagen and laminin immunostaining. The Equine Hoof, Equine vet. J. Supplement 27

- Rendano V. T., and Grant B., (1978) The equine third phalanx : its radiographic Appearance,
Am. J. Vet. Rad. Soc. 19:125
- Rodebaugh, H. D., (1938) Surgical treatment of chronic laminitis Vet. Med. 33 p(288—28/9)
- Runnells R. A., Monlux, (1967) Principles of Vet. Path. 7th Ed. The Iowa state
University Press, U.S.A.
- Saleh, A. S., (1982) Incidence and treatment of prevalent hoof affection in equines at assut
province M. V. Sc. Thisis, Fac. Vet. Med. Assut University
- Scott, E. A., Mcdole M., and Shire, (1979) A review of third phalanx fractures in the horse, J.
Am. Vet. Med. Assos. 174:1337
- Shuttle Worth A. C., (1966) Seedy toe in intern. Encyle. Vet. Med. Vol.5 p(2668-2669)
- Soliman I. A., (1989) Clinical observation on hoof deformities in donkeys Assiut, Veterinary
Medical Journal 21 No. 42.
- Stick J. A., Jann H. W., Scott E. A., (1982) Pedal bone rotation as a prognostic sign in
laminitis in horses. J Am. Vet. Med. Assoc. 180:251-253.
- Stump A., John E., (1967) Anatomy of the Normal Equine Foot, Including Microscopic
Feature of the Laminar Region. Journal of the American Veterinary Medical
Association 151, no. 12: 1588-1598
- Walker, and Geiser, (1986) Equine Laminitis and Associated Hypertension:A Review.
Journal of the American Veterinary Medical Assoc. 166, No. 1:56-57

Waters, J. W., Lebel, J. L., and Park, R. D., (1969) Morphometric analysis of radiographic changes in the distal phalanges of quarter horses with lower leg lameness Am. J. Vet. Rad. Soc., 19:66

Weaver, A. D. (1969) Fracture of the equine pedal bone Eq. Vet. J., 1:283

White, N. A., and Baggett, N., (1983) A method of corrective shoeing for laminitis in horses Vet. Méd./ S. A. C. p(773-778)

Youich, J. V., Hilbert B. J., and McGill (1982) Fractures of the distal phalanx in horses, Aust. Vet. J., 59:180

الإصابات الجراحية للحافر في الخيول مع الإشارة الخاصة إلى طرق علاجها

إصابات الحافر تلعب دوراً هاماً في الخيول وتمثل نسبة عالية من حالات العرج لذلك خطط هذا البحث لإلقاء الضوء على نسب الإصابات التي تبدو أكثر شيوعاً والتي ينتج عنها خسارة اقتصادية في الفصيلة الخيلية .

أجرى هذا البحث لفحص ٨٢٣ حيواناً من الفصيلة الخيلية (٤٩٧ حصان و ٢٤٢ حمار و ٨٤ بغل) لتحديد أنواع الإصابات.

تم جمع هذه الحيوانات من نوادي فرسية القوات المسلحة بالقاهرة والإسكندرية والمستشفى البيطري الرئيسي للقوات المسلحة ومستشفى بروتوكول الخيري لعلاج الحيوان بالإسكندرية ومستشفى كلية الطب البيطري بإفيينا .

وقد توصلت نتائج البحث والتشخيص للإصابات الجراحية للحافر في الخيول إلى الآتي :

وجد ٩٠ حالة التهاب حاد في الحافر وتمثل ١٠,٩٤ % و ١١٧ حالة التهاب مزمن في الحافر وتمثل ١٤,٢ % و ١٤٧ حالة تشقق في الحافر وتمثل ١٧,٨ % و ١٢٨ حالة عفن الحافر وتمثل ١٥,٥٥ % و ٤٦ حالة دمل الحافر ويمثل ٥,٥ % و التهاب القصبه المزمن والمرض الزورقي في ٥ حالات وسرطان الحافر ٤ حالات وتمثل ٠,٥ % وخز مسمار في نصل الحافر ٨٨ حالة وتمثل ١٠,٧ % وتشوهات في الحافر ٢ حالة وتمثل ٣ % وكسر في عظم الحافر ١ حالة ٠,١ % نمو نسيجي زائد ٧ حالات ٠,٨ %

ومن نتائج البحث يتضح أن الإصابات الأكثر شيوعاً في الخيول الالتهاب المزمن في الحافر ١٤,٢ %
عفن الحافر ١٤,٩ تشقق الحافر ١٧,٨ % التهاب حاد في الحافر ١٠,٩ % , وخز نعل الحافر ١٠,٦٩ %
دم الحافر ٥,٥٩ % تشوهات الحافر ٣ % .

بينما الأكل شيوعاً كسر عظمة الحافر ٠,١ وقد تم التدخل الجراحي تحت تأثير المهدئات المختلفة
لعلاج هذه الإصابات وقد تم شفاء معظم هذه الإصابات .

ومن نتائج هذا العمل أن أسباب إصابات الحافر في الخيول يمكن إرجاعها إلى عدم الاهتمام بتقليم
الحافر و تركيب الحدوة بالإضافة إلى تشوهات الحافر وعدم الانتظام في العليق بالإضافة إلى مضاعفات وخر
مسمار نعل الحافر ودمل الحافر وأيضاً طريقة المعيشة .

وطبيعة الجو المحيط بالحيوان كما و ان نوعية التربة لها تأثير على أمراض الحافر مثل حالات
عفن الحافر اد يرجع السبب الرئيسي لها إلى وجود رطوبة والأرض الطينية بينما تبين ان حالات تشقق
الحافر تكثر في المناطق الصحراوية والمناطق الجافة حيث التعرض المفاجئ للرطوبة ثم الجفاف يؤدي إلى
تشقق الحافر كذلك تبين ان عفن الحافر شائع في الحيوانات التي ليس بها حدوة بينما دمل الحافر سببه أساساً
ترك الحدوة لمدة طويلة في الحافر .

تحت إشراف



أ.د / سمير راشد نوح

أستاذ ورئيس قسم الجراحة

كلية الطب البيطري

جامعة الإسكندرية



أ.د/ رمضان السيد عبد الواحد

أستاذ مساعد الجراحة

كلية الطب البيطري

جامعة الإسكندرية

" الاصابات الجراحية للحافر فى الخيول مع
الاشارة الخاصة الى طرق علاجها "

مقدمة من


ط.ب/ هيثم ابراهيم على شاور

للحصول على درجة
الماجستير فى العلوم الطبية البيطرية

فى
الجراحة

لجنة المناقشة والحكم على الرسالة


موافقون



١. السيد أ.د/ كمال الدين أحمد فؤاد
أستاذ الجراحة المتفرغ
بكلية الطب البيطرى - جامعة القاهرة



٢. السيد أ.د/ مصطفى محمد قاسم
أستاذ الجراحة
كلية الطب البيطرى - جامعة الإسكندرية



٣. السيد أ.د/ سمير راشد نوح
أستاذ ورئيس قسم الجراحة
كلية الطب البيطرى - جامعة الإسكندرية
والمشرف على الرسالة



٤. السيد د. / رمضان السيد عبد الواحد
أستاذ مساعد الجراحة
كلية الطب البيطرى - جامعة الإسكندرية
والمشرف على الرسالة



٥١

الإصابات الجراحية للحافر فى الخيول مع الإشارة الخاصة إلى طرق علاجها

رسالة علمية

مقدمة إلى الدراسات العليا بكلية الطب البيطرى - جامعة الإسكندرية
إستيفاء للدراسات المقررة للحصول على درجة

الماجستير فى العلوم الطبية البيطرية

فى

الجراحة

مقدمة من

ط.ب/ هيثم إبراهيم على شاور

2006